

Chair Side Teeth Bleaching- A Case Report

Iqra Raza*

Consultant Dental Surgeon, Dentistry (Oral Maxillofacial Surgery), Noor Dental Clinic, Karachi, Pakistan

***Corresponding Author:** Iqra Raza, Consultant Dental Surgeon, Dentistry (Oral Maxillofacial Surgery), Noor Dental Clinic, Karachi, Pakistan.

Received: September 06, 2021; **Published:** February 26, 2022

Abstract

The options range from most conservative to surgical ones. Due to anxiety and fear of surgical procedures patient usually demands more conservative options. Dental bleaching is the non-invasive method to reconcile a smile of discolored teeth. The aim of this case report is to describe in office/chair side Bleaching using Beam white advanced teeth whitening kit by using 25% of hydrogen peroxide in young patient. The result was successful by the end of 2 cycles each of 15 minutes.

Keywords: Chair Side Teeth Bleaching; Anxiety; Hydrogen Peroxide

Introduction

Dental bleaching is the non-invasive method to reconcile a smile of discolored teeth.

Case Report and Discussion

A 20-year-old female with multiple Pits and Fissure caries and satisfactory Oral hygiene report to my clinic with chief complain of discoloration of teeth.

On clinical examination moderate white bands in labial surface of teeth were observed. Patient was told about invasive and non-invasive options and details involving bleaching, at the conclusion the patient felt that in office bleaching would meet her needs.

Primarily carious tooth was identified, and vitality testing were done. Patient upper right lateral incisor was carious, I planned for restoration and Zirconium crown over it. Radiograph were also done in digital Periapical Xray. Professional cleaning and prophylactic polishing were performed before the bleaching procedure. I prescribed NSAIDS prior to treatment as postoperative sensitivity is unpredictable.

Patient was reassured and counselled for the procedure time and complication if any. Consent was taken, Pretreatment shade

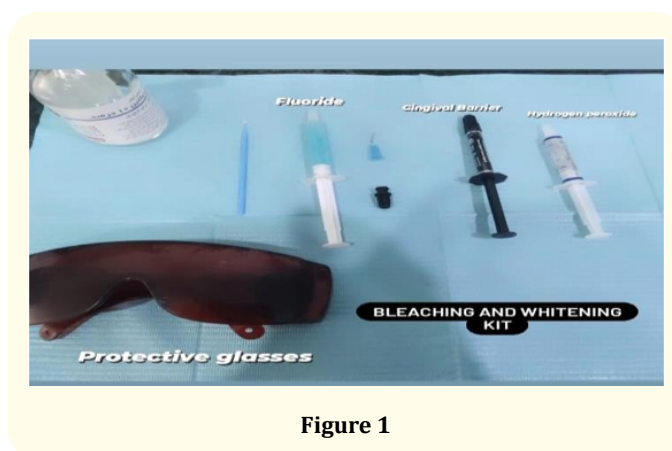


Figure 1

decided and documented. A self-supporting cheek retractor was placed in patient mouth, for isolation and visibility. Teeth were rinsed and dried thoroughly.

Gingival barrier applied in gum margin as a separator with the help of syringe (Applicator) and cured with LED based curing light, it sealed each of the tooth involved in treatment and prevents acid whitener from seeping in to surrounding gum tissue. The targeted area was Intercanine region of upper and lower teeth. Additional isolation with cotton rolls and suction tip were also performed.

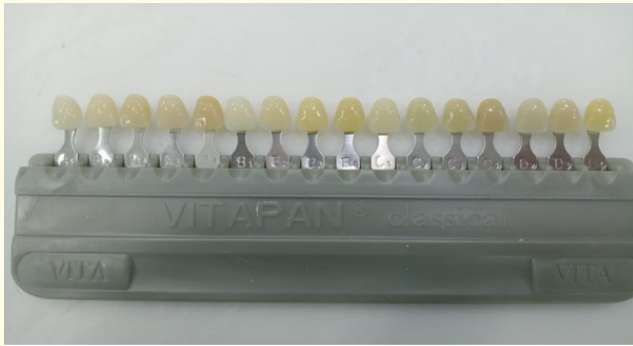


Figure 2

Hydrogen peroxide application

After this step we applied bleaching agent 25% Hydrogen Peroxide dabbed and painted on each exposed tooth being treated. The acid was cured first cycle of curing was of 15 minutes. The result was satisfactory, I reapplied the bleaching material, cured it again for 15 minutes and got the desired result.

Preop picture and postop picture

The exposed bleaching material was suctioned off and washed as well. After postoperative picture the cheek retractor was removed. Patient was shown the result at the end and beautiful smile was achieved.

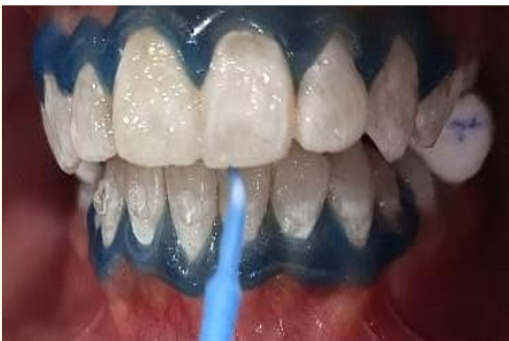
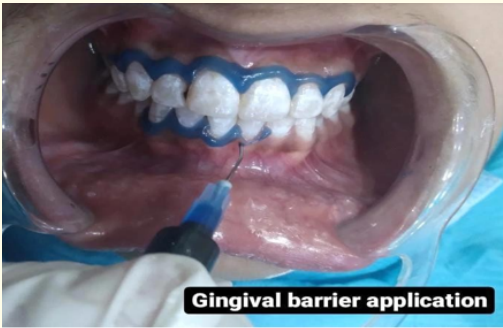

Figure 3

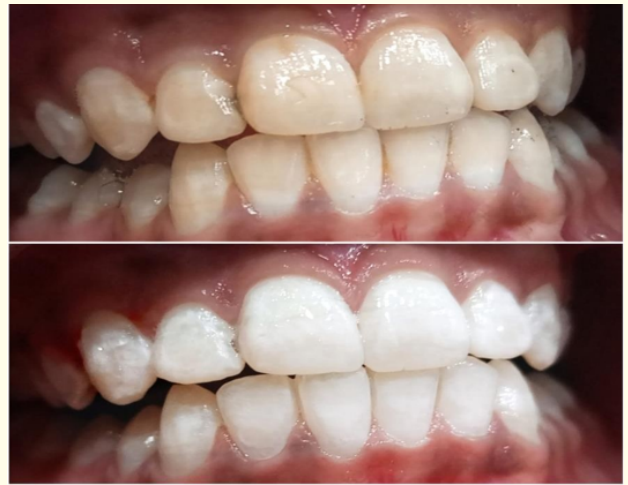

Figure 4

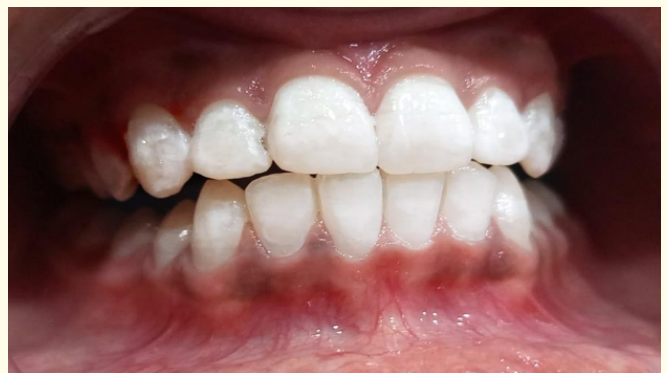

Figure 5

Desensitizing agent in the form of fluoride was applied on teeth to prevent postoperative sensitivity. Postoperative instructions were given that patient should refrain from consuming staining agents like coffee, colas, tea, tobacco or smoking for first few hours after the bleaching. Analgesics and counseling of mild sensitivity in post op period were discussed. I recalled the patient after 2 weeks for follow up [1-6].

Conclusion

In the conclusion I must say (in office bleaching) is superior to any technique, but data required for further study on it, the advantage of this includes Dental Practitioner control on it, less time required and immediate results were achieved that enhance patient satisfaction.

Bibliography

1. ADA Council on Scientific Affairs. Tooth Whitening/Bleaching: Treatment Considerations for Dentists and Their Patients. American Dental Association, 2009.
2. Dawson P, et al. A clinical study comparing the efficacy and sensitivity of home vs combined whitening. Operative Dentistry. 2011;36(5):460-466.
3. Tavares M, et al. Light augments tooth whitening with peroxide. Journal of the American Dental Association. 2003;134(2):167-175.
4. https://www.researchgate.net/publication/274974017_Vital_Tooth_Bleaching_A_Case_Report
5. https://www.researchgate.net/publication/346987150_In_office_teeth_bleaching_A_case_report
6. https://www.researchgate.net/publication/352782716_BLEACHING_WITH_375_HYDROGEN_PEROXIDE-A_CASE_REPORT

Volume 5 Issue 3 March 2022

© All rights are reserved by Iqra Raza.