

## Case Report: Immediate Implants in Compromised Hard and Soft Tissue Aesthetic Zone

**Dr. B Arunkumar, M.D.S\***

*Pearls Dentistry, Chennai, India*

**\*Corresponding Author:** Dr. B. Arunkumar, M.D.S Managing director, Pearls Dentistry, Chennai, India.

**Received:** September 06, 2019; **Published:** September 26, 2019

### Abstract

Tooth loss in the aesthetic region is often a traumatic experience for the patient. Trauma to upper anterior teeth is common, and their loss can lead to significant aesthetic and functional problems. Immediate Implant placement in the aesthetic zone with compromised hard and soft tissues is a challenging situation requiring careful planning to get the desirable outcome. Immediate implant placement is a well-accepted treatment modality that has been shown to have high cumulative survival rates ranging 92 - 100% [2-5]. This is a case report of 28 year old female, who lost her front tooth in a road traffic accident and the how the bone regeneration was successfully achieved along with immediate implants placement.

**Keywords:** Immediate Implants; Bone Regeneration; PRF; Bone Grafts

### Introduction

Tooth loss in the aesthetic region is often a traumatic experience for the patient. Dental trauma can result in loss of tooth regardless of best attempts in maintaining and preserving the compromised tooth [1]. Trauma to upper anterior teeth is common, and their loss can lead to significant aesthetic and functional problems. Implant Dentistry is a fast developing field with current, expert coverage on every aspect of implant treatment offering the most successful and long-term result for replacement of missing teeth.

Immediate implant placement is a well-accepted treatment modality that has been shown to have high cumulative survival rates ranging 92-100% [2-5]. First introduced in 1976, the placement of an implant immediately after tooth extraction offers the advantages of treatment time reduction and potentially increased patient satisfaction and treatment acceptance [6]. In many cases, it has been the preferred surgical protocol over the classical delayed implant placement proposed by Branemark [7].

In most of the traumatised cases, lot of structural damages are observed in which regenerative procedures are necessary. The most widely used regenerative materials are PRF along with bone

grafts. Platelet-rich fibrin (PRF), a second-generation platelet concentrate, is obtained from autologous blood with simplified processing without the need for biochemical blood handling [8]. PRF accelerates and activates the growth factors that improves wound healing.

### Case Report

A 28 year old female visited our clinic after a road traffic accident. Clinical examination revealed avulsion of right central incisors and crown fracture involving the whole crown of right lateral incisors.

### Surgical phase

The surgery was carried out under conscious sedation with local anaesthesia. Following the aseptic state in the operation area, patient was injected intravenously with midazolam.

The first treatment step was the careful extraction of fractured 12 under Local anaesthesia. This was carried out by carefully elevating a full thickness muco periosteal flap using periosteal elevator and removing the root with an appropriate forceps. The labial cortical plate was fractured and the fragment was used as an autograft

subsequently mixed with allograft and PRF. The extraction socket as well as the socket of the avulsed tooth was carefully debrided, well irrigated with saline and implants were planned. Osteotomy sites were prepared and implants (Zimmer implant 3.7 \* 13 mm, 3.7 \* 11.5 mm) were placed in 11, 12, respectively. It was ensured that during implant placement adequate primary stability was achieved. After placement of implants, PRF membrane were trimmed mixed with the bone graft and placed in the bony defect whereby the jumping distance was filled. Collagen membrane were also trimmed and packed both labially and lingually. Flaps were approximated using Vicryl sutures.

Postoperative management comprised of oral antibiotics (Augmentin 625 mg, twice daily for 5 days) and anti-inflammatory medication (Combiflam, 400 mg thrice daily for 5 days). Patient was instructed to rinse her mouth with 0.12% chlorhexidine solution daily for a week from 24hrs post-surgery to avoid clot disturbance.

### PRF preparation

Patient's blood sample was collected by drawing blood from the antecubital vein in vacutainer tubes prior to surgery. Immediately after the blood was drawn the tubes were centrifuged at 2700 rpm for 12 mins in centrifuger (REMI).

PRF was procured from the tube and transferred to the kit. The weighted press in the kit is intended to express serum from the fibrin clot in a controlled manner and to form thin compressed layer of Platelet Rich Fibrin. The PRF is then trimmed, mixed with bone graft, serum and then placed in the defect site and over the implants.

### Post-operative healing

The site was examined for uneventful healing. Healing was satisfactory and there was no post-operative complications.

Three months later, the implant site was exposed by slightly elevating the flap, healing abutment was then connected to allow the emergence of implant through soft tissue, thereby facilitating access to the implant from the oral cavity. After the placement of the provisional crown, the peri implant site was observed for many weeks to adapt well to the crown.

Six month follow up both clinically and radiographically demonstrated healthy peri-implant soft tissue and a well integrated implant with adequate bone formation. Subsequently, the provisional crowns were replaced by metal free porcelain crowns. The patient was reviewed after 1 year and hard and soft tissue integrity was well maintained.

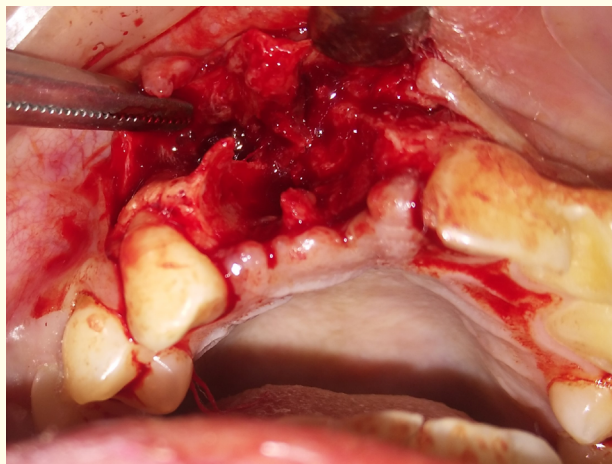


Figure 1

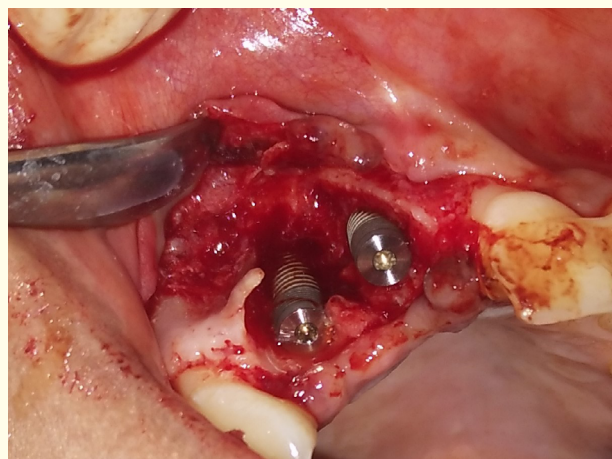

Figure 2

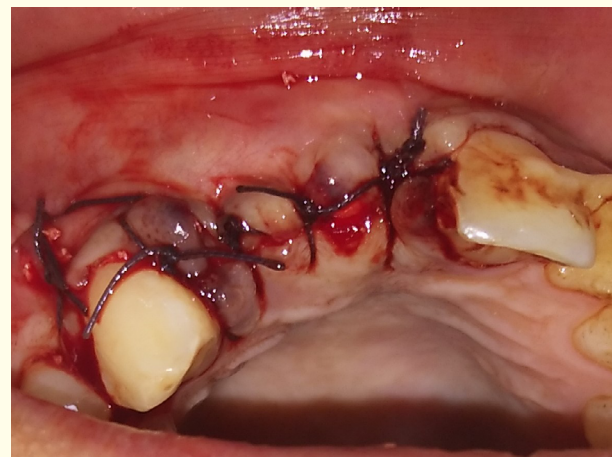

Figure 3

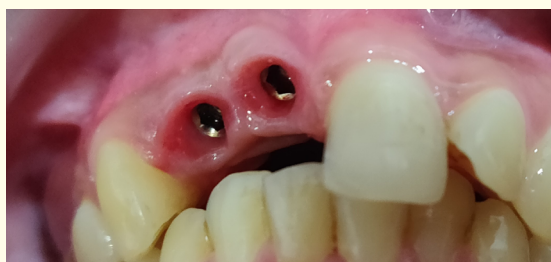


Figure 4

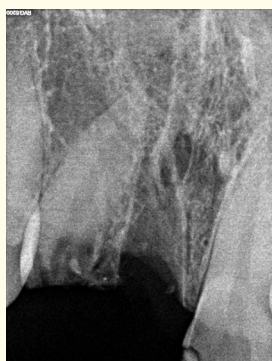

Figure 5

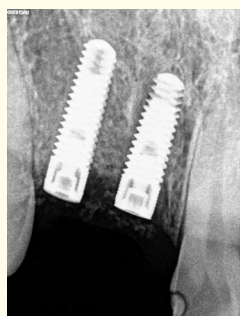

Figure 6

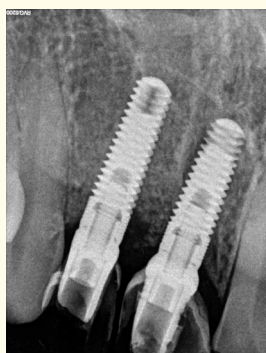


Figure 7

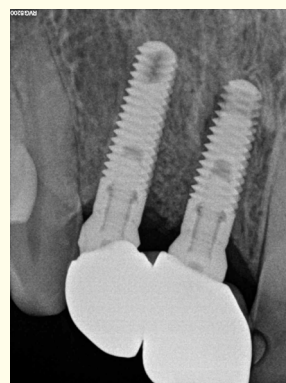


Figure 8

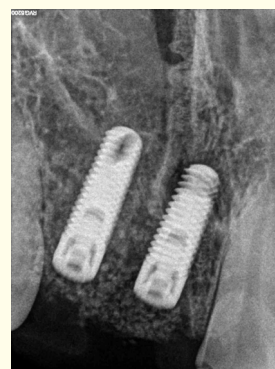

Figure 9

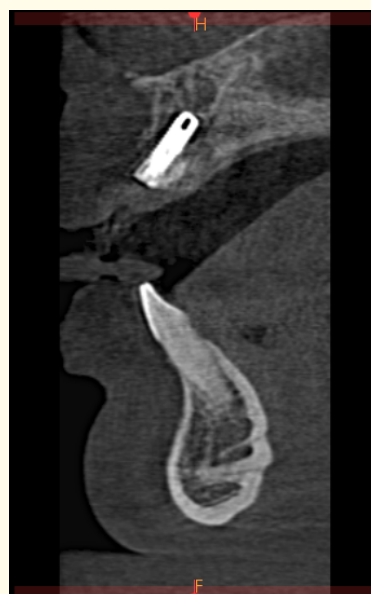

Figure 10

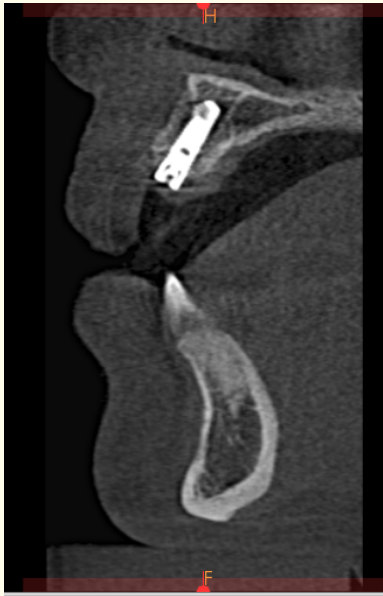

Figure 11

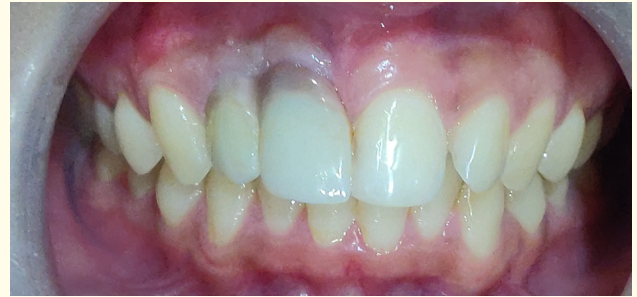

Figure 14

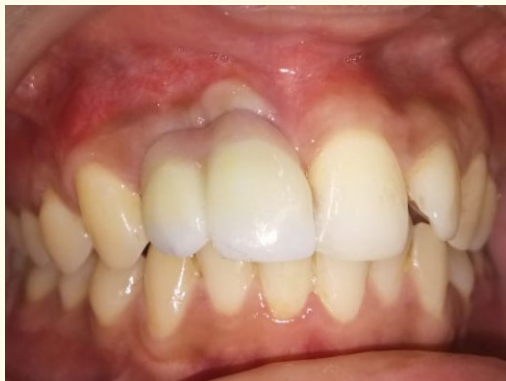

Figure 12

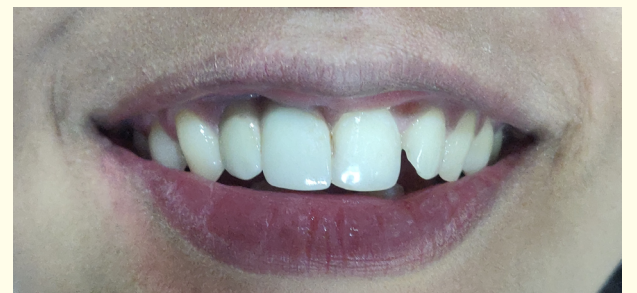

Figure 15

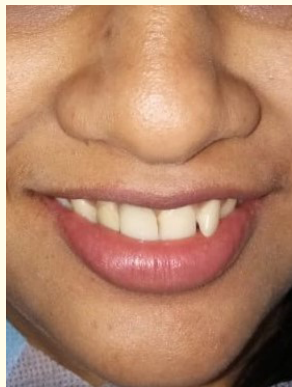

Figure 13

### Discussion

In implant dentistry, Immediate Implants present a challenge especially in compromised hard and soft tissue situations and in aesthetic zone. Traditionally, compromised teeth were extracted and the resultant sockets were left to make well for four to six months before placing implants. However, marked alterations in the edentulous ridge after extraction that includes reduction in the bucco-lingual dimensions, alveolar bone height coupled with patients demands has shifted our focus to immediate implants with PRF and bone grafts. Number of factors identified as patient dependent or clinical dependent is necessary for the esthetic success of immediate implant [9]. Some of the significant advantages of immediate implant placement are less waiting period for socket healing, shorter period of edentulousness, reduced total treatment time, preservation of alveolar bone height and width [10].

A space between the implant surface and the bone walls may occur when the implant is placed in a fresh socket. The size of the gap is both influenced by the organisation of the alveolus and by the design and width of the implant [11].

To achieve a good esthetic and functional rehabilitation, a proper case selection as well as high surgical skill was required. AlQahtani, *et al.* reported that the placement of implants imme-

diately in fresh sockets with immediate loading in periodontally compromised patients is a promising treatment modality, but the practitioner should follow a very strict protocol [12]. Our present case was very challenging due to the loss of labial cortical plate, hence the implant was placed more palatally and the gaps were filled with regenerative materials. Different types of biocompatible graft materials have been commonly used in bone regeneration procedures prior to implant placement. The autograft, allograft, alloplast, and xenograft materials all have reported success, alone or in combination for bone augmentation [13,14]. Also, immediate implants placed with PRF leads to both soft and hard tissue regeneration. Arora et al. reported PRF helps in rapid soft tissue regeneration, diminishes vertical bone loss, and improves early wound closure, which helps in achieving an esthetic outcome and better patient acceptance [15].

Iasella, *et al.* 2003 compared normal socket healing and augmented sockets and concluded that unaugmented sockets decreased in width by an average of 1.7 mm while grafted sites decreased by 1.2 mm [16]. Furthermore, Nevins, *et al.* 2006 confirmed in a clinical study using computerized tomographic scans that the ridges of nongrafted extraction sockets showed more than 20% loss of crest height [17].

The 6 months follow-up of 11 and 12 region showed clinically healthy peri-implant soft tissues, no signs of peri-implant infection but a small mucosal recession was observed in 11 and 12 that was overcome by gingival porcelain thereby providing an overall pleasing aesthetic treatment outcome. The periapical radiograph showed stable bone crest levels.

## Conclusion

In the present case, immediate implants was successfully placed in the compromised aesthetic region. The combination of PRF along with bone grafts promoted both soft and hard tissues at the implant sites. This protocol should be used with caution due to the lack of long term results, and a number of prerequisites and guidelines need to be considered. To assure the success of this approach more long-term perspectives and controlled clinical studies are needed especially for aesthetic outcomes. Also deficiency in soft and hard tissue can be addressed predictably when a staged approach is performed and when combined as a single step can lead to aesthetic deficiency which have to be managed prosthetically resulting in less than ideal situation.

## Bibliography

1. Aws Alani, Rupert Austin, and Serpil Djemal. Contemporary management of tooth replacement in the traumatized dentition. *Dent Traumatol.* 2012;28(3):183-192.
2. Bianchi AE, Sanfilippo F. Single-tooth replacement by immediate implant and connective tissue graft: A 1-9-year clinical evaluation. *Clin Oral Implants Res.* 2004;15(3):269-277.
3. Botticelli D, Renzi A, Lindhe J, Berglundh T. Implants in fresh extraction sockets: A prospective 5-year follow-up clinical study. *Clin Oral Implants Res.* 2008;19(12):1226-1232.
4. Lang NP, Pun L, Lau KY, Li KY, Wong MC. A systematic review on survival and success rates of implants placed immediately into fresh extraction sockets after at least 1 year. *Clin Oral Implants Res.* 2012;23(5):39-66.
5. Lindeboom JA, Tijook Y, Kroon FH. Immediate placement of implants in periapical infected sites: A prospective randomized study in 50 patients. *Oral Surg Oral Med Oral Pathol Oral Radiol Endod.* 2006;101(6):705-710.
6. Schulte W, Heimke G. The Tubinger immediate implant. *Quintessenz.* 1976;27(6):17-23.
7. Brånemark PI. Osseointegration and its experimental background. *J Prosthet Dent.* 1983;50(3):399-410.
8. Choukroun J, Diss A, Simonpieri A, et al. Platelet-rich fibrin (PRF): A second-generation platelet concentrate. Part IV: Clinical effects on tissue healing. *Oral Surg Oral Med Oral Pathol Oral Radiol Endod.* 2006;101(3):56-60.
9. Kan JYK, Rungcharassaeng K, Deflorian M, Weinstein T, Wang HL, Testori T. Immediate implant placement and provisionalization of maxillary anterior single implants. *Periodontol* 2000. 2018;77(1):197-212.
10. Barziley I, Graser GN, Iranpour B, Nutiella J, Proskin H. Histological and clinical assessment of implants placed into extraction sockets. *Journal of Dental Research.* 1990;69:290.
11. Dohan DM, Choukroun J, Diss A, Dohan SL, Dohan AJ, Mouhyi J, Gogly B. Platelet-rich fibrin (PRF): A second generation platelet. *Oral Surg Oral Med Oral Pathol Oral Radiol Endod.* 2006;101(3):e37-e44.
12. AlQahtani NA. Immediate Implant Placement with Immediate Loading in Periodontally Compromised Patients: A Literature Review. *J Int Oral Health.* 2016;8(5):632-638.

13. Schropp L, Kostopoulos L, Wenzel A. Bone healing following immediate versus delayed placement of titanium implants into extraction sockets: a prospective clinical study. *Int J Oral Maxillofac Implants*. 2003;18(2):189-199.
14. Block MS, Kent JN. Placement of endosseous implants into tooth extraction sites. *J Oral Maxillofac Surg*. 1991;49(12):1269-1276.
15. Arora S, Bali S, Thukral P, Bhushan A, Taneja M, Aggarwal P. A Comparative evaluation of immediate implant in fresh extraction socket with and without platelet rich fibrin: A clinical and radiographical study. *IJOICR*. 2016;7(3):48-58.
16. Iasella JM, Greenwell H, Miller RL, Hill M, Drisko C, Bohra AA, et al. Ridge preservation with freeze-dried bone allograft and a collagen membrane compared to extraction alone for implant site development: A clinical and histologic study in humans. *J Periodontol*. 2003;74(7):168-177.
17. Nevins M, Camelo M, De Paoli S, Friedland B, Schenk RK, Parma-Benfenati S, Simion M, Tinti C, Wagenberg B. A study of the fate of the buccal wall of extraction sockets of teeth with prominent roots. *Int J Periodontics Restorative Dent*. 2006;26(1):19-29.

**Volume 2 Issue 10 October 2019**

**© All rights are reserved by B Arunkumar.**