

Complementary Application of Medical Ozone in Dentistry, for a Dental Exodontics in Diabetic Patient Type II

Denis Jim Palomino Gutiérrez, Henry Jeancarlo Obispo Ruiz, Jose Luis Flores Mesia, Aldair Alfred Lopez Malaga, Aurelio Medina Gonzáles*, Israel Ribeyro Vásquez and María Angélica Fry Oropeza

Founding Member and Scientific Director of the Peruvian Academy of Stomatological Ozone Therapy, Second Specialty in Periodontics and Oral Implantology, Researcher and Lecturer, Lima, Peru

***Corresponding Author:** Aurelio Medina Gonzáles, Founding Member and Scientific Director of the Peruvian Academy of Stomatological Ozone Therapy, Second Specialty in Periodontics and Oral Implantology, Researcher and Lecturer, Lima, Peru.

Received: October 26, 2022; **Published:** November 07, 2022

Abstract

Diabetic patients have to be treated with a prevention protocol since they are susceptible to infections.

Different preventive measures are used such as: premedication, mouthwashes, scaling and root planing, prophylaxis, defocusing (exodontia of pieces with loss of support and periodontal insertion), karyological treatment, oral rehabilitation. Among the delocalization protocol in diabetic patients, where extractions are to be performed, it is established as a rule after the evaluation to perform a panoramic radiograph, eventually a periapical radiograph (when you want to evaluate a sign located in the piece). Degree of infection in the tooth and type of premedication, elimination of predisposing factors of periodontal disease through prophylaxis, elimination of the stone. Despite all the preventive protocols, there is always a latent condition of complications, for this reason publications have been found in different scientific articles on the use of ozone gas as a complementary element in disinfection of oral pathogens, oxygenation of tissues and a beneficial effect on healing.

With this objective, we found an innovative and complementary protocol to reduce the bacterial load before dental extraction with ozone gas topication at the level of the gingival margin and papillae, both at the level of the preoperative preparation (prophylaxis, scaling, scaling and root planing). as at the time before the extraction, and once the extraction, coagulation formation and ozonation of the surface and gingival mucosa of the tooth extracted, a success rate greater than 50% is expected, compared to the protein structures of the pathogens.

In the following work, we are going to address the issue of medical ozone applied in dentistry, in a controlled patient with diabetes, for which the concentration of medical ozone in % 30Ug was used to help reduce the bacterial load, due to the properties that it has this gas against oral tissues and against pathogens, in this case of greater relevance, such as an insulin-dependent diabetic patient.

Keywords: *Medical Ozone; Surgery; Protocols; Teeth; Disinfection; Tooth Extraction; Diabetes; Cicatrization; Oxidation; Oral Hygiene Index*

Introduction

Ozone therapy has been used in multiple modalities in dentistry.

It is characterized by the reduction of adverse effects.

Ozone is associated with the formation of reactive oxygen molecules, which influence cell metabolism and trigger an antioxidant response, promoting tissue regeneration and enhancing the antimicrobial effect.

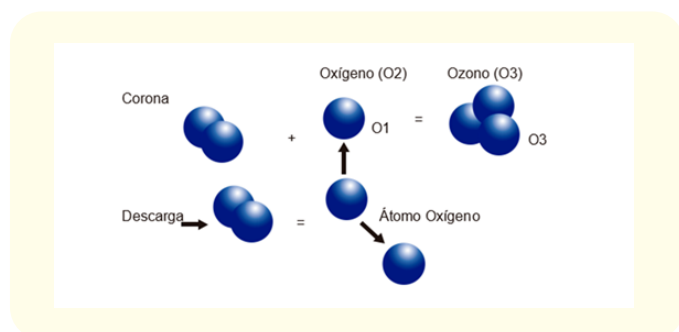
The objective of this work is to reduce the risk of post extraction infection by taking advantage of the benefits of ozone gas as an oxidative element against pathogens and oxygenating element against oral tissues, which allows reducing the risk of post extraction infection and in turn favors healing, which in diabetic patients would allow to achieve a better post exodontia predictability.

Ozone (O₃) is a molecule of three oxygen atoms, paired in a transitory way (it volatilizes), when it volatilizes, it will decompose into an O₂ molecule (two oxygens) and an oxygen atom.

The O₂ molecule behaves as an oxygenating agent against human and animal cells, and the remaining oxygen atom behaves as an oxidant against pathogens, producing decomposition of protein structures [1].

The generation of medical ozone

It is artificially generated by entering a flow of medical oxygen in the electronic field of an ozone generator device, adjustable to different electronic intensities, producing different concentrations of trivalent oxygen, as a final product which is known as ozone gas [3].



Administration mode

Once the ozone is generated, it can be used in dentistry and medicine in different ways: As ozone gas directly, as an aqueous solution dissolved in distilled water, or as ozone oil. These application forms are used individually or in combination to treat dental diseases.

Ozone in gas

It has a great germicidal capacity against bacteria, viruses and fungi, due to its high oxidizing power emanated by its third oxygen at the time of its volatilization [2]. The route used is through ozone gas insufflated directly to the surface of the epithelial tissue or blood clot.

Ozonated water

Ozone is kept in suspension in distilled water for times, between minutes and hours depending on the concentration, maintaining greater stability at temperatures below 0. Ozone in water is used at the same time as ozonation for washing oral tissues such as wounds or post extractions, since it acts by rapidly decomposing, thus allowing its use in contact with said tissues [4]. This ozonated water has proven to be a great disinfectant agent with pow-

erful antimicrobial action against bacteria, viruses and fungi. The germicidal capacity of ozonated water is highly dependent on the concentration of ozone dissolved in the water [4,7].

One of the great advantages of using ozonized water as a disinfectant agent is that it has great cell and tissue biocompatibility, much greater than that of other disinfectants widely used in dentistry such as sodium hypochlorite or chlorhexidine digluconate.

Developing

Ozone in surgery

Ozone was found to accelerate wound healing. After a tooth extraction or any surgical procedure, the area is irrigated and insufflated, which promotes faster healing without complications. Ozone therapy is beneficial for the treatment of refractory osteomyelitis in the head and neck, in addition to treatment with antibiotics, surgery, and hyperbaric oxygen. It also increases the benefits of surgical and pharmacological treatments that cause complete healing of injuries [6].

Oral healing with ozone

Healing is a multicellular process that develops after an injury; in the oral mucosa, this process is coordinated by fibroblasts, endothelial cells, macrophages, and platelets. Wounds in the oral cavity are subject to a large amount of commensal flora that can influence inflammation and granulation tissue formation, thus prolonging repair processes [5]. It is proven that bacteria affect healing in the oral cavity.

For this reason, bacterial elimination with ozone can act directly or indirectly on connective tissue cells and accelerate healing in oral wounds.

Clinical Case

A 76-year-old male patient, from Lima, with a history of being allergic to NSAIDs, in addition to being a hypertensive patient, insulin-dependent diabetic, does not refer complications to anesthesia. He arrives due to discomfort in the left area of the jaw. In the intraoral evaluation, a partially edentulous patient is observed, at the level of piece 3.6 a furcation lesion with type III mobility and in piece 3.7 extensive caries that compromises approximately 60% of the crown, also with evidence of type III dental mobility, also presence of gingivitis at a general level also evidence of bacterial plaque dental calculus.

Case report

First date

The patient enters the dental environment after developing the patient admission protocol in times of COVID, once seated in the dental unit, the mouthwash protocol with chlorhexidine + cpc mouthwash for 1 minute is carried out. The diagnosis and treatment plan for the reason why the patient attends the consultation is made during the intraoral evaluation, in which it is concluded that the teeth will be extracted 3,6, 3,7 due to the degree of commitment they present the compromised dental pieces and the evident poor oral hygiene of the patient and corroborated by the oral hygiene index, a prophylactic antibiotic pre-medication is indicated for 3 days prior to the elimination of local factors (plaque and dental calculus). Medication consisting of clindamycin 300 mg every 8 hours for 3 days, ketorolac 10 mg 6 tablets, 1 every 12 hours for 3 days, and chlorhexidine + cpc mouthwash diluted in a glass of water every 12 hours (after tooth brushing).

Likewise, it is indicated and explained (informative Power point) to the patient the possibility of complementing their treatment using complementary medical ozone therapy for use applied in dentistry in order to reduce the load of pathogens and thereby promote better healing to which it was supplemented with an informed consent form.

Second date

Steps: Once the patient's admission protocol to the office in times of covid has been carried out, we proceed to the mouthwash protocol, then a prophylaxis and elimination of dental calculus is carried out with ultrasound, then proceeding to the installation of the surgical field for the extraction, 3 cartridges were used anesthesia without vasoconstrictor (mepivacaine).

A dental prophylaxis was carried out and subsequently the application of ozone in gaseous form directly to the gingival surface of the affected pieces to reduce the bacterial load, then the syndesmotomy of piece 3.6 was carried out with a thin straight plunger, to then proceed to use a parrot beak forceps with buccal-lingual movements, then proceeded to extract the piece; Next, we proceeded to curette and wash with ozonized water as well as the suture. Then, piece 3.7 was extracted following the same protocol as piece 3.6. Once the suture was finished, ozonation was finally carried out on the surface of the exodontiated and sutured pieces.

The patient was then treated with the routine protocol (antibiotics and analgesics) 600 mg clindamycin with 60mg ketorolac in an ampoule once a day for three days, after which oral clindamycin in capsules once every 8 hours for 3 more days (the oral route is later than the injectables).

In the postoperative period after one week he did not present any complications, good healing and re-epithelialization, when the stitches were removed, there was slight bleeding and no recurrent infections were observed.

Discussion

- The main biological actions of ozone in the human body are bactericidal, virucidal, fungicidal, analgesic, antimicrobial, immunostimulant, bioenergetic, biosynthetic, detoxifying and antihypoxic.
- The bactericidal efficacy of ozone in gas form has been shown to be effective after one, seven and fourteen days of application, which supports its use as a complementary therapy in disinfection.
- Ozone water reduces the microbial load and organic matter in biological environments and facilitates the healing of wounds caused by surgical interventions thanks to its biophysiological properties.
- Ozone can be used as an irrigant in endodontics affecting gram (-) bacteria and with a low effect on gram (+) bacteria.
- Applying ozone in surgery reduces the chances of presenting dry socket, however, it does not reduce the chances of post extraction inflammation.

Conclusion

The complementary protocol of medical ozone in dentistry applied to oral surgery as an innovative protocol demonstrated to reduce the risk of infection after extraction in an insulin-dependent diabetic patient with allergy to NSAIDs and hypertensive and according to the reviewed literature with the beneficial properties of ozone. used in dentistry meets the expectations of predictability in reducing complications in dental extraction procedures.

Bibliography

1. Medina A, Fry M. Ozonoterapia en odontologia: tratamiento alternativo en periodoncia. JPAP; 2020.

2. Esp EG, Souto M, Esp EG, Tellez Carlos Luis, Sanchez Izabel, Esp EG, Rosales Erma, LIC At Estomatol Gomez Zaide. Aplicación del ozono en alveolitis dentaria. Multimed revista medica. Granma. 2018.
3. Pérez B, Rodriguez G, Paneque MR, Perez A. La ozonoterapia en estomatología. MEDISAN. 2009;13(4).
4. Mendes J. Efectividad y aplicación del ozono en odontología - revisión en endodoncia. Ozone Therapy Global Journal. 2020;10(1):197-205.
5. Hernandez S, Fernandez L. Ozonoterapia en Tratamiento Periodontal Clínico. Ozone Therapy Global Journal. 2020;10(1):289-300.
6. Sánchez B F. (n.d.). Aplicaciones De La Ozonoterapia En La Odontología. Uft.Cl, 2021.
7. Martinez Judit, Weisser Mark. Seguridad Durante El Tratamiento Con Ozonon En El Consultorio Dental. Revista Cubana De Estomatología. 2013;50(4):397-407.