

## Remission of Gingival Overgrowth after Non-surgical Periodontal Treatment: Follow-up of 7-years

Irineu Gregnanin Pedron<sup>1\*</sup>, Maria Eugenia da Silva Cezere<sup>2</sup>, Estevam Rubens Utumi<sup>2</sup>, João Marcelo Ferreira de Medeiros<sup>1</sup> and Caleb Shitsuka<sup>3</sup>

<sup>1</sup>Professor of Periodontology, Stomatology and Implantology, College of Dentistry, Universidade Brasil, São Paulo, Brazil

<sup>2</sup>Private Practice, São Paulo, Brazil

<sup>3</sup>Professor of Periodontology and Cariology, College of Dentistry, Universidade Brasil, São Paulo, Brazil

**\*Corresponding Author:** Irineu Gregnanin Pedron, Professor of Periodontology, Stomatology and Implantology, College of Dentistry, Universidade Brasil, São Paulo, Brazil, **Email-id:** igpedron@alumni.usp.br.

**Received:** September 04, 2019; **Published:** September 26, 2019

### Abstract

Gingival overgrowth is characterized by tissue enlargement of inflammatory origin and can assume varied sizes and are usually treated by surgical excision. The recurrence of the lesion is usually justified by the persistence of the etiological agent, such as the presence of biofilm and dental calculus, causing chronic periodontal disease. The purpose of this article is to present the case of a patient with gingival overgrowth concomitant with chronic periodontal disease, whose therapy was the basic periodontal treatment, causing remission of a large part of the lesion, and surgical excision in order to elucidate the final diagnosis and eliminate injury completely. The present case demonstrates the importance of the oral hygiene process - constituted by the use of conventional, interdental and tuff toothbrushes, and dental floss - and the periodontal treatment prior to the surgical excision of the lesion, improving the clinical and histopathological aspects and favoring the prognosis of the lesion.

**Keywords:** Gingival Overgrowth; Oral Hygiene; Home Care Dental Devices; Toothbrushing; Periodontal Treatment

### Introduction

Gingival overgrowth can be classified as tissue enlargement of inflammatory origin, being characterized clinically by the increase of gingival tissue that emerges from the interdental papilla, but which may affect the entire keratinized gingiva; of firm, yet resilient and mobile consistency; staining of pink to erythematous; granular or smooth surface, with a loss of normal appearance of the gingival surface ("orange peel"). Generally asymptomatic, except for inflammation or trauma during mastication, and may still present bleeding during the probing [1-5]. It can cover the coronary portion of affected teeth, creating deep pseudo-pockets that hinder oral hygiene and favor the accumulation of biofilm and dental calculus, causing the promotion of periodontal diseases and the installation of carious lesions [1]. Etiopathogenic factors

include poor oral hygiene, accumulation of biofilm and dental calculus, considered as a low-intensity chronic traumatic factor [1-5]. In addition, irritative factors such as maladaptive prostheses, orthodontic appliances and edges of excessive restorations may invade the biological space of the periodontium and make it difficult to remove the biofilm [2-5].

The histopathological pattern of inflammatory gingival overgrowth is composed of parakeratinized stratified squamous epithelium, which emits long and thin projections towards the lamina propria formed by dense, well-cellular and collagenate connective tissue, presenting chronic inflammatory infiltrate consisting of polymorphonuclear leukocytes. Areas of fibrosis, hyperemia, edema and hemorrhage may also be observed [2,3].

The recommended treatment for gingival overgrowth is surgical removal [1-11]. However, other therapeutic modalities may be employed or associated. The purpose of this article is to present the case of a lesion diagnosed as gingival overgrowth, in which the remission of the lesion was collected through conventional periodontal treatment prior to surgical removal.

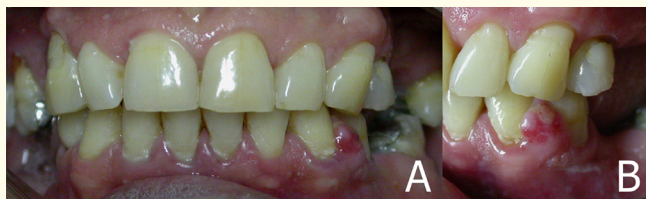**Case Report**

A 58-years-old Caucasian male patient attended at the private clinic complaining of gingival injury.

Clinically, the patient had an asymptomatic tumor mass, with the following characteristics: solid, resilient, slightly ulcerated, erythematous staining, with whitish membrane, smooth and globose surface and sessile base, with a 6-month history, measuring approximately 6 mm diameter, affecting the interdental vestibular papilla between teeth 33 and 34. Signs of moderate chronic periodontitis with plaque, dental calculus, purulent suppuration and dental absences were observed (14, 15, 25, 26, 35, 37, 44, 45, 46 and 47), with upper and lower removable partial dentures (Figure 1).

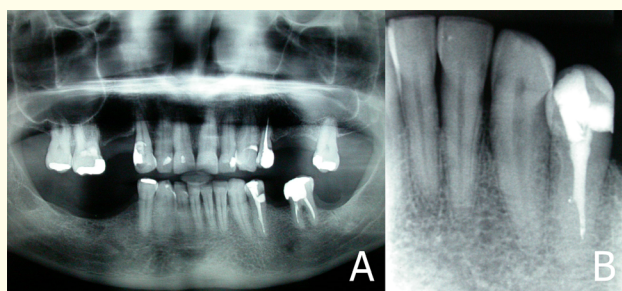
Regarding medical history, the patient reported case of breast cancer of the mother and two sisters.

Periodontal treatment prior to removal of the lesion was proposed by means of surgical excision. Initially, the oral hygiene orientation consultation was performed, using dental plaque coloring (Figure 3) and oriented the patient with the conventional, tuft and interdental toothbrushes and dental floss (Figures 4-7). After 10 days, remission of the lesion size was observed, by reduction of the inflammatory process. Periodontal treatment (quadrant per session, under local anesthesia) was initiated, starting with the ultrasonic instrument followed by manual scaling and root planing with Gracey's curettes (Figure 8).

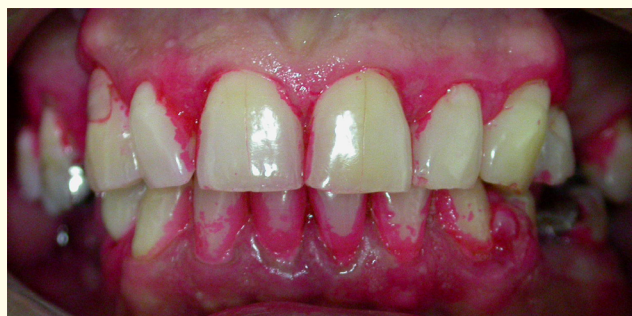

**Figure 1:** Initial clinical features (A: frontal view; B: left lateral view).

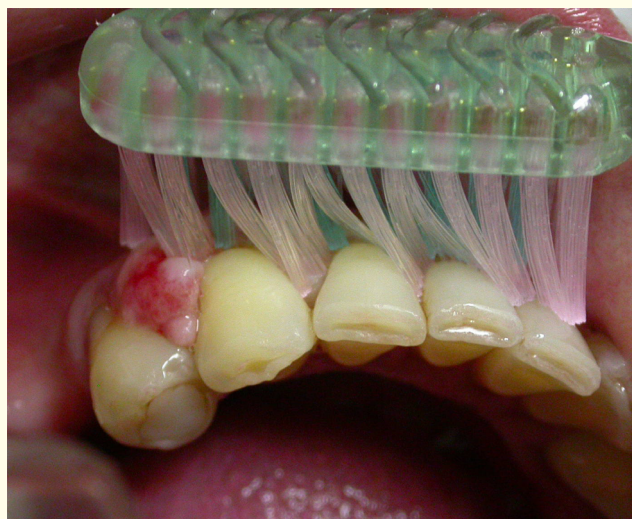Radiographically, radiolucent image around the teeth inherent to periodontal bone loss was observed, as well as radiopaque images suggestive of dental calculi around the teeth (Figure 2).



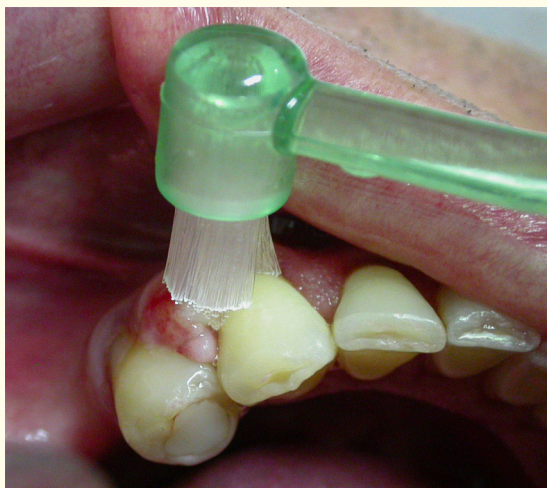
**Figure 2:** Initial radiographic aspects (A: panoramic radiograph; B: periapical radiography).



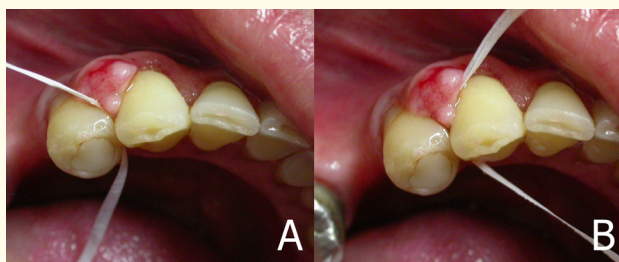
**Figure 3:** Bacterial plaque colouring.



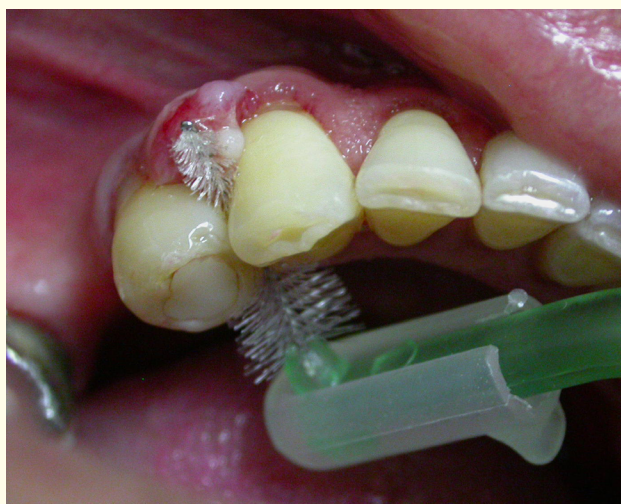**Figure 4:** Using the manual brush (Bass technique).



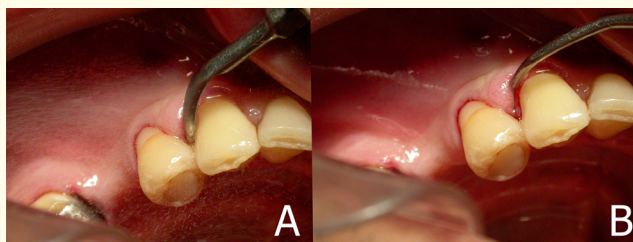
**Figure 5:** Use of the tuft brush.



**Figure 6:** Use of the dental floss around the lesion (A: mesial face of tooth 34; B: distal face of tooth 33).

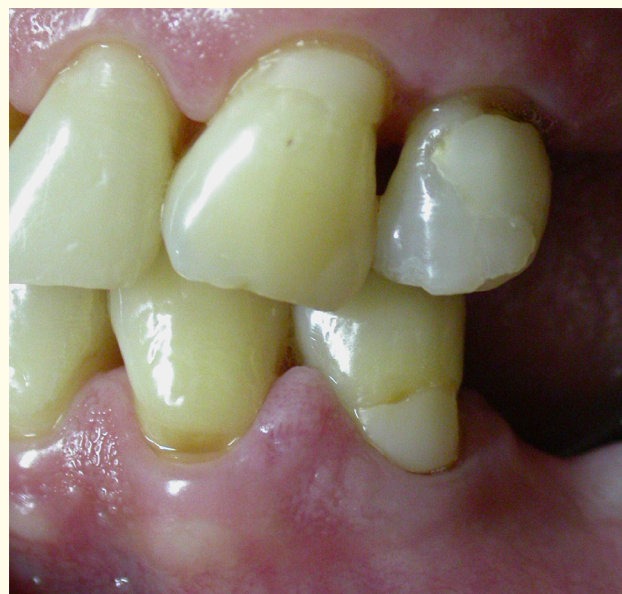

**Figure 7:** Interdental brush use.

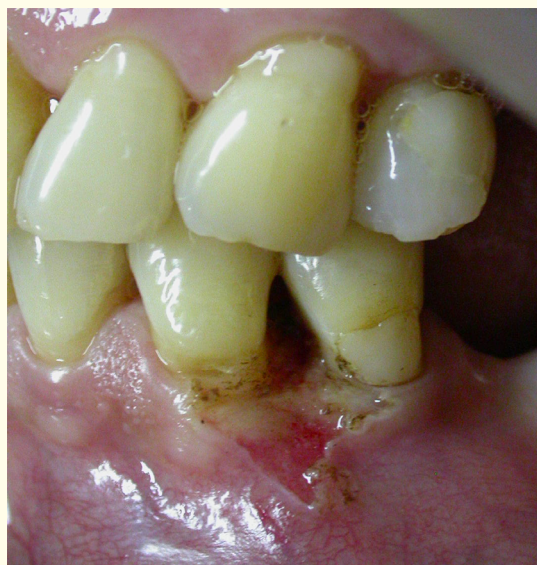

**Figure 8:** Periodontal treatment (A: ultrasonic scaling; B: manual scaling).

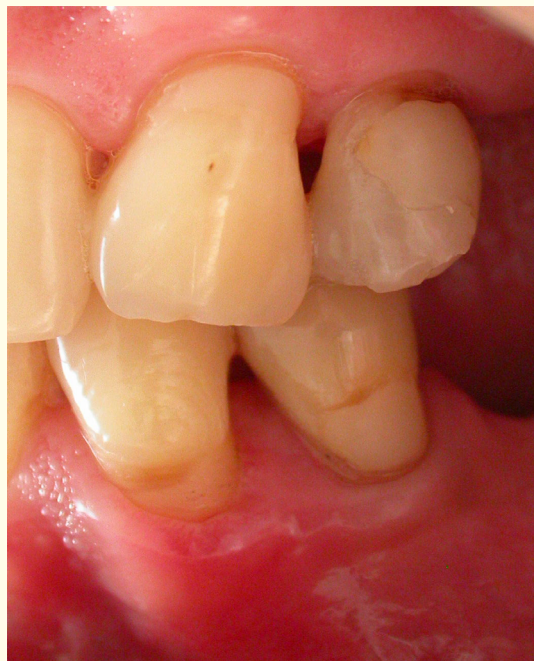After complete periodontal treatment (Figure 9), surgical excision of the lesion was suggested, in order to elucidate the final diagnosis. Under local anesthesia, the lesion was removed by incision at the base of the lesion and then cauterized by the use of an electric scalpel (Figure 10). The lesion was fixed in 10% formalin and sent to the Laboratory of Surgical Pathology, Faculty of Dentistry, University of São Paulo. The histopathological examination revealed a fragment of mucosa coated by parakeratinized stratified squamous epithelium, presenting areas of acanthosis and elongation of the epithelial ridges. The lamina propria consisted of dense connective tissue with parallel collagen fibers. Areas of intense mixed inflammatory infiltrate were also observed (Figure 11). The diagnosis was inflammatory gingival overgrowth.



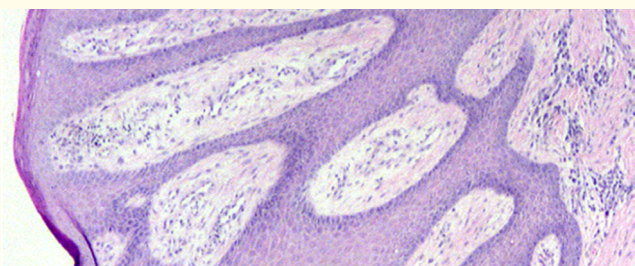
**Figure 9:** Reduction of the inflammatory process and subsequent remission of the lesion.



**Figure 10:** Immediate postoperative: Removal of the lesion and cauterization by the electric scalpel.



**Figure 12:** Patient in maintenance phase and periodontal control for 7 years, with no signs of recurrence of the lesion.



**Figure 11:** Histopathological appearance of inflammatory gingival overgrowth (original staining: HE, lower magnification).

The patient was evaluated after 20 days, presenting satisfactory repair of the region. After 7 years of treatment, the patient is still undergoing preservation, with annual evaluations, with no signs of recurrence (Figure 12).

### Discussion and Conclusion

Several lesions make up the differential diagnosis, among them pyogenic granuloma, peripheral giant cell lesion (in the early stages) and peripheral ossifying fibroma [3,4,6,8,9]. These lesions show very similar clinical signs and etiologies (tissue growths of traumatic origin, such as persistent inflammation), and are usually treated in the same way by means of surgical excision.

In addition to surgical excision as the main therapeutic modality recommended, it was suggested a total surgical excision of the lesion through curettage [2-4], gingivectomy [1-6,12] or flap surgery [2,12]. The use of other techniques were also verified, such as electrocautery [1,12] and surgical laser (CO<sub>2</sub> or Nd:YAG) [1,2,4,6,10-12]. The use of surgical laser has been increasing as an alternative treatment to soft tissue surgeries in the oral cavity due to advantages such as hemostasis and better visualization of the surgical field; minor postoperative edema and pain, reducing the need for postoperative medication; tolerance of the patient; reduction in anesthetic amount; and satisfactory tissue healing [6,10].

However, several authors emphasized the importance of periodontal conduction, from the motivation and instruction of the patients regarding oral hygiene, and the execution of periodontal treatment proper (scaling and root planing), with the purpose of removing the local irritative factor periodontal disease) and maintenance of the results obtained with the treatment (periodontal support or periodontal maintenance) [1-4,6,7,11,12].

In the present report, the Bass brushing technique was initially advocated in the oral hygiene instruction, which consists of the positioning and introduction of the brush bristles inclined at 45°

towards the gingival sulcus and anteroposterior displacement in short rhythmic movements [1-7], as can be seen in figure 4. In addition, the use of dental floss and interdental toothbrush were considered. The techniques were demonstrated in the mouth of the patient himself, and the plaque colouring was used, and the patient was instructed to perform the procedures daily.

After the periodontal treatment (procedures of oral hygiene and scaling and root planing), a reduction in the size of the lesion and the inflammatory process were observed, in which the gingival tissue presented clinical characteristics closer to normal. It was reported a relationship between the removal of the local irritative factors and the reduction of the inflammatory process, associated to the reduction of the severity of inflammatory gingival overgrowth [1,6,12]. In addition, the reduction of the need for surgical treatment of the lesion becomes possible, given the possibility of complete remission. Such procedures may also, when there is a need for surgical intervention, cause reduction of trans-surgical bleeding and avoid the possibility of recurrence of the lesion [3,6].

Despite the reduction of the lesion after the periodontal treatment and the clinical features suggestive of inflammatory gingival overgrowth, we chose to perform the excisional biopsy and submit the lesion to the anatomic-pathological examination due to the patient's family history of cancer, in order to exclude the possibility diagnosis of other proliferative processes or neoplastic increases and decrease the anxiety and negative expectation of the patient.

Recurrence of inflammatory gingival overgrowth is not uncommon and can be avoided by supporting periodontal therapy (reinforcement of oral hygiene and scaling and root planing sessions), maintaining treatment results [1,3-5]. The recurrence of the lesion was related to non-removal of irritative factors or incomplete excision of the lesion [4,6].

## Bibliography

1. Pedron IG, Aburad A, Tortamano IP, Borsatti MA, Adde CA. Clinical management at the dental care of patients undergoing therapy with phenytoin. *Rev Odonto*. 2005;13(25):59-64.
2. Pedron IG, Horliana ACRT, Horliana RF, Aburad A, Tortamano IP. Gingival hyperplasia in patients under orthodontic treatment - Therapeutic indications. *Ortodontia SPO*. 2008;41(1):33-37.
3. Pedron IG, Gomes T, Loureiro CCS, Aburad A, Adde CA. The periodontal disease how etiopathogenic factor to the inflammatory gingival hyperplasia. *Rev Odonto*. 2009;17(34):76-81.
4. Pedron IG, Utumi ER, Tancredi ARC, Perez FEG, Marcucci G. Non-neoplastic proliferative gingival processes in patients undergoing orthodontic treatment. *Dental Press J Orthod*. 2010;15(6):80-87.
5. Silveira CB, Pedron IG, Adde CA, Perez FEG. Considerations at dental care in patients receiving nifedipine therapy. *Rev Inst Ciênc Saúde*. 2004;22(3):243-246.
6. Reyes A, Pedron IG, Utumi ER, Aburad A, Soares MS. Piogenic granuloma: focus on periodontal disease as an etiological factor. *Rev Clín Pesq Odontol*. 2008;4(1):29-33.
7. Pedron IG, Torrezani A, Aburad A, Utumi ER, Silva LPN, Adde CA. Dental management in renal transplant patients: proposal of clinical-periodontal protocol. *Revista Perio News*. 2008;2:277-282.
8. Binnie WH. Periodontal cysts and epulides. *Periodontol* 2000. 1999;21:16-32.
9. Coleman GC, Flaitz CM, Vincent SD. Differential diagnosis of oral soft tissue lesions. *Tex Dent J*. 2002;119(6):484-503.
10. Pedron IG, Carnaval TG, Adde CA, Imparato JCP. Therapeutic proposal in lesions of the oral cavity: laser surgery. *J Bras Clin Odontol Integr*. 2006;10(10):196-198.
11. Malek R, El Houari B, Kissa J. Periodontal management of cyclosporin-A induced gingival overgrowth: a nonsurgical approach. *Case Rep Dent*. 2019;8609547.
12. Chang CC, Lin TM, Chan CP, Pan WL. Nonsurgical periodontal treatment and prosthetic rehabilitation of a renal transplant patient with gingival enlargement: a case report with 2-year follow-up. *BMC Oral Health*. 2018;18(1):140.

**Volume 2 Issue 10 October 2019**

**© All rights are reserved by Irineu Gregnanin Pedron., et al.**