

In-Office Tooth Bleaching Treatment Using Light-Activated Hydrogen Peroxide Agent combined with ambulatory treatment: A Case Report

Zouiten S, Ben cheikh Ahmed H*, Gnaba I, Smaoui M, Bougatef H and Boughzela A

Restorative Dentistry and Endodontics, Dental Surgery Department, University Hospital Farhat Hached Sousse, Tunisia

*Corresponding Author: Ben cheikh Ahmed H, Restorative Dentistry and Endodontics, Dental Surgery Department, University Hospital Farhat Hached Sousse, Tunisia.

Received: December 29, 2018; Published: January 22, 2019

Abstract

Tooth bleaching has become one of the most popular cosmetic procedures offered in dental practice. Bleaching agents are provided for in-office and at home treatments. Manufactures have introduced different concentration of hydrogen peroxide hanging from 10% to 38%. In office hydrogen peroxide decomposition can be accelerated with applying a physical activation such as light or heat, which provides energy for the reaction. The aim of this report is to describe an in-office tooth bleaching treatment using light-activated hydrogen peroxide agent combined with ambulatory treatment in severe fluorosis anterior teeth.

Keywords: Bleaching; Hydrogen Peroxide; Light Activation; Fluorosis

Introduction

The smile and teeth esthetics, including tooth color, has become of great importance to patients, resulting in increased demands for tooth bleaching. There are several products and methods described for bleaching vital teeth, including different concentrations of bleaching agents, application times, application modes and kind of acceleration used with the bleaching agent.

Minoux and Serfaty recognize that tooth bleaching is a very complex process that depends on several factors; the bleaching agent pH, the application method, the thickness of the bleaching agent to the enamel, the fluctuation of irradiation, the length of photo-activation, the tooth size, the selective absorption of the irradiation wavelength, among others. Further studies are needed regarding the new wavelength of the laser lights and the bleaching products to determine the protocol and the most favorable terms in order to improve the tooth bleaching process [1].

So far, two techniques of tooth bleaching have been described. The first one is the ambulatory technique (at home) that needs an intraoral device (tray) to apply the peroxide gel. This technique is more cost-effective and the value of the dental color obtained is sustained for long periods. But important changes in this value are not observed before the 7th day of treatment. The second technique is known as the in-office technique. It is practiced by a dentist who can using photoactivation. This one allows changes in the enamel color from the first session. However, there is strong evidence that the value of the dental color obtained is not sustained after 6 months [2].

This article describes the treatment of a case of dental dyschromia by bleaching using a light-activated hydrogen peroxide agent combined with an ambulatory treatment.

Case History

A 24 year old female was referred to the Department of Dental Medicine for a dental bleaching treatment. It was the first time she requested this cosmetic procedure. The examination revealed good oral hygiene with no carious lesions. The vitality test was positive for all anterior teeth. Anamnesis on the fluorides revealed that the patient is from a city where water concentration in fluorides is high. So, after anamneses and clinical examination, the patient was diagnosed with severe fluorosis according to modified Dean Index (DI) (Figure 1) using the criteria recommended by the World Health Organization (WHO). As the patient wanted to have the most conservative treatment possible, we opted for in-office bleaching regimen with 32% hydrogen peroxide and light activation (WHITEsmile Flash®) combined to an ambulatory treatment with WHITEsmile home bleaching®.

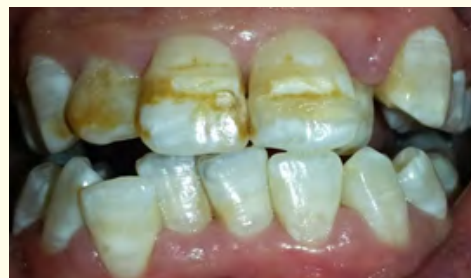

Figure 1: Initial case: Notice the severe fluorosis according to (DI).

First, the tooth color shade was verified using the color shade guide of the flash® in-office bleaching by visual examination (Figure 2).

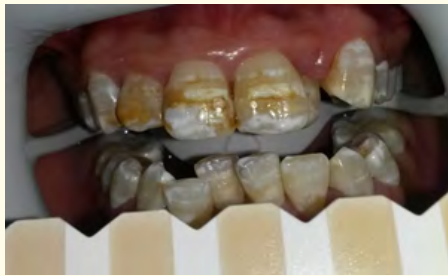

Figure 2: Color shade selection using the color shade guide or the bleaching kit.

Next, we used a retractor to ensure a relative isolation and to provide a full view of the anterior and posterior teeth. Then, we applied light-curing gingival mask (Gingiva protector flash®) at

the contour of the gingival tissue in an attempt to avoid contact between the bleaching agent and the gingiva (Figure 3).

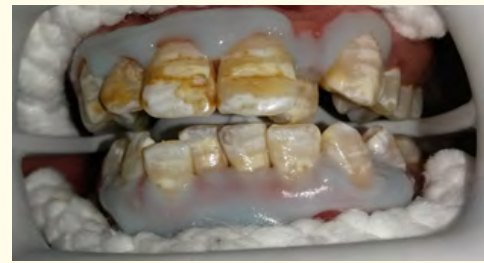

Figure 3: Isolation of the teeth using a lip retractor and a light-curing liquid Dam (Gingiva protector flash®).

Later, green colored 32% hydrogen peroxide (flash® White-Smile) was applied to cover the buccal surface of all the anterior teeth plus the pre-molars. The gel was then activated with the flash high-power LED Whitening Lamp (WHITEsmile®). The lamp was set on pulse program for 15 minutes. Then, the gel changed its color showing that it has lost its active state (Figure 4).

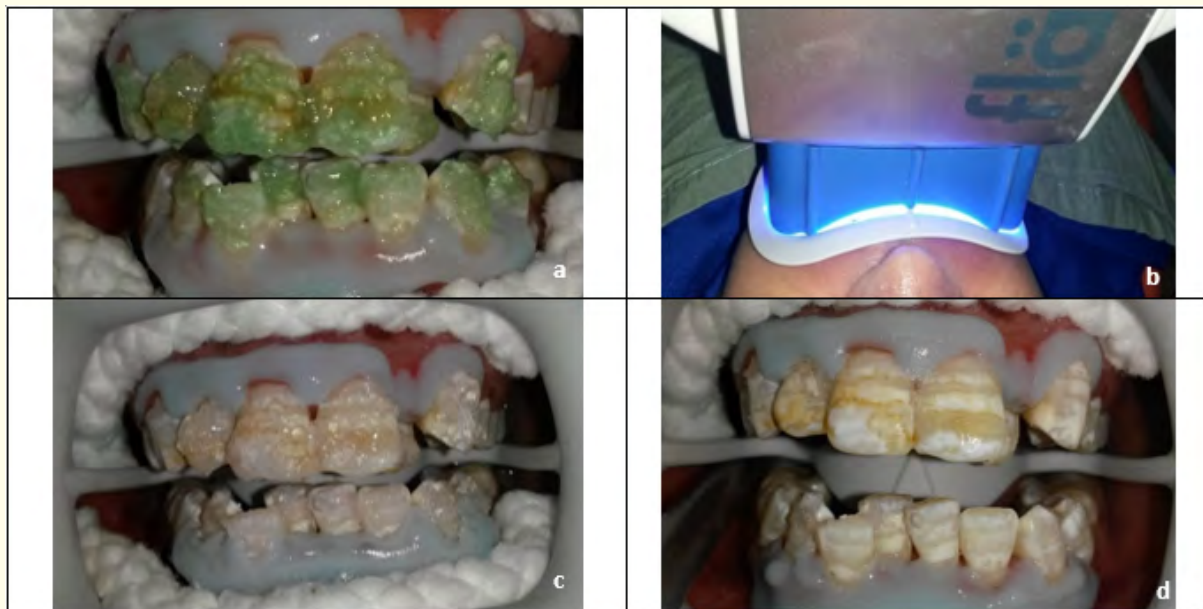

Figure 4: Application of the 32% flash peroxide gel on the buccal surface of the premolars and anterior teeth (a); Next, activation of the gel with the Flash Whitening Lamp for 15mn (b); Change in the color of the gel(c); Then, the gel can be removed first with an aspirator tip and cleaned with some gauze (d). The same steps from (a) to (d) are repeated two more time.

Finally, the gel was removed from the teeth surface with an aspirator tip and cleaned with some gauze, and the bleaching gel was newly applied following the same protocol.

After the third application of the bleaching gel, the basic color has remarkably brightened. However, the brown spots of fluorosis persisted as yellowish ones (Figure 5).

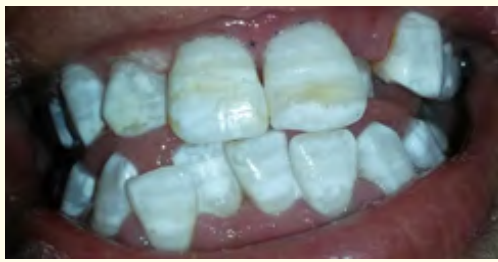

Figure 5: Final result after in-office bleaching.

At the end of the treatment, we applied the After Whitening Mousse (WHITeSmile®) over the teeth to prevent any sensitivity following bleaching (Figure 6). The patient was also given a Whitening toothpaste (flash® White-Smile) containing 1100 ppm fluoride to act against any sensitivity at home.

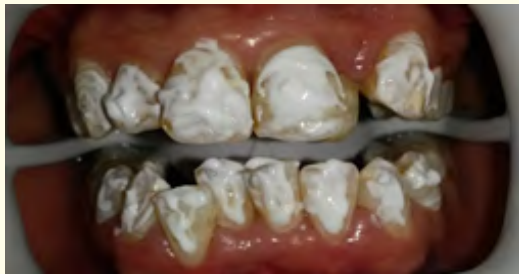

Figure 6: Application of the after-whitening mousse.

The patient was received 7 days later for a follow-up (Figure 7). In order to remove persistent yellowish spots and maintain long-term results, we decided to carry on an ambulatory treatment using the home whitening of WHITeSmile® Germany. To perform this, special maxillary and mandibular full arch trays were constructed and fitted to the patient (Figure 8).

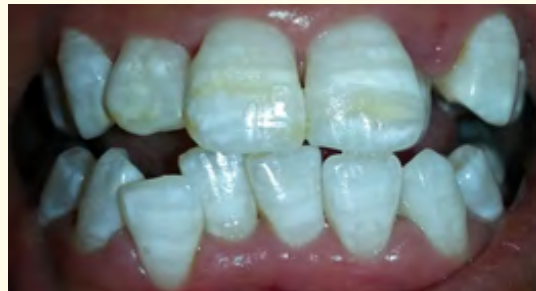

Figure 7: One week after bleaching; notice the stability of color.

The treatment consisted of 12 sessions, in which 16% carbamide peroxide gel was applied overnight for 4 hours. The result obtained showed a remarkable improvement in the shade with disappearance of spots and homogenization of color (Figure 9). Clinical follow-up after 6 months and 18 months showed color stability (Figure 10 and 11).

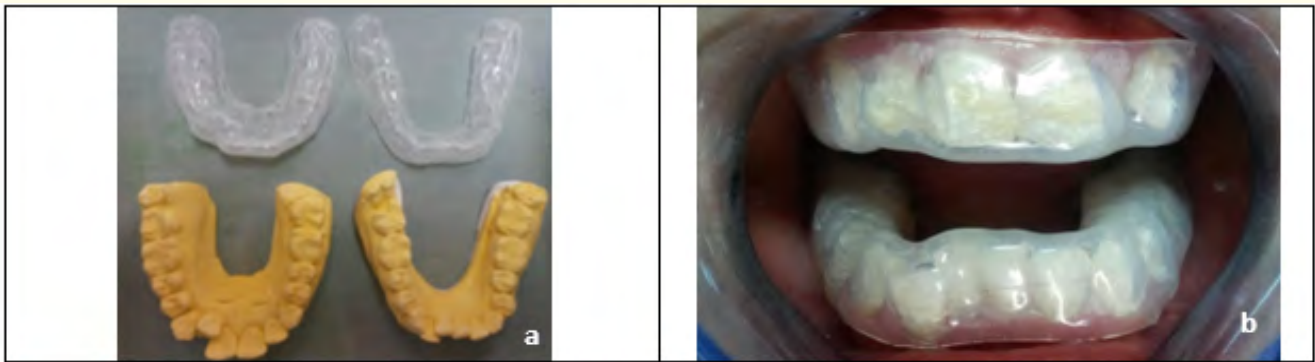


Figure 8: a- Preparation of maxillary and mandibular trays for home bleaching. b- Fitting the trays in mouth.

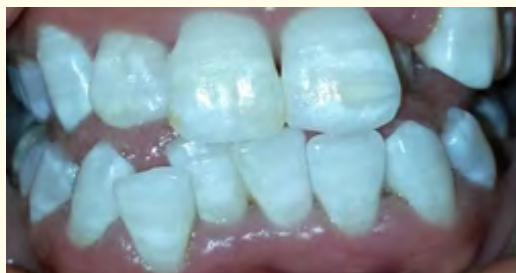

Figure 9: The result after 2 weeks of home bleaching.

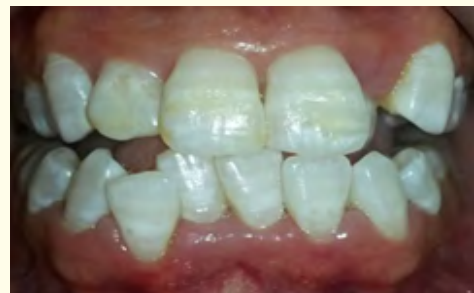

Figure 10: The result after 6 months.

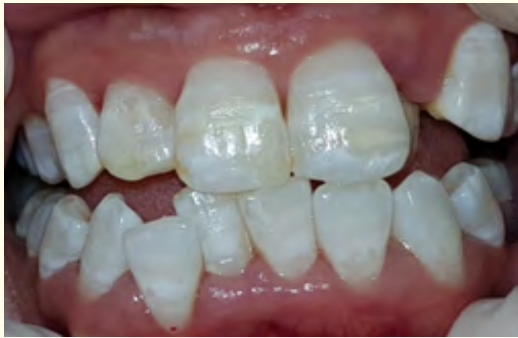

Figure 11: The result after 18 months.

Discussion

In case of dental fluorosis, several therapeutic alternatives are proposed. The combination of dental bleaching techniques and microabrasion is an interesting conservative solution to reestablish color in fluorosis-affected teeth. However, in this case, we opted for a more conservative treatment which is an in-office bleaching regimen with light activation combined to an ambulatory treatment.

For many years, heat or light has been used to speed the breakdown of hydrogen peroxide for a faster bleaching result. Many devices, such as halogen curing lights, light emitting diode (LEDs), diode lasers, argon lasers and plasma arc lamps have been used [3]. In fact, Light activation accelerates and enhances the power of the bleaching agent. Available studies do not allow to have an ultimate judgment about whether or not tooth bleaching can be safely accelerated by whatever additional light activation [2].

Indeed, controversy surrounds the success of light sources. Some researchers believe that they are effective in the bleaching process, while others believe that only certain lights are effective, and still others report no effect of differential light activations [2].

Some studies proved that in the bleaching protocols, a light source is widely used to reduce the treatment time by increasing the release of oxygen, the ion responsible for the bleaching effect. Kossatz, *et al.* found faster bleaching for the LED/laser group than that without light activation after the first bleaching session [4]. In fact, the light sources are not responsible for tooth bleaching. The rationale behind the benefits of light activation is that a small fraction of light is absorbed by the bleaching product and its energy is converted to heat ($\text{H}_2\text{O}_2 + 211\text{kJ/mol} \rightarrow 2\text{HO}^*$). Most likely, this is the main mechanism of action of all light-activated bleaching procedures, leading to increased release of hydroxyl radicals through a rise in temperature (thermocatalysis) [5]. However, increasing the

temperature of the bleaching gel causes a temperature increase in the pulp chamber at the same time, which can irreversibly damage the vital pulp if it exceeds a particular degree [6].

With regard to the sensitivity problem, previous studies reported that the bleaching gel itself acts as a light absorbent barrier that provides an insulating effect and decreases the temperature within the pulp regardless of the light source. In addition, the presence of water and HP in the gel could provide a cooling effect upon the evaporation of these components during the light-activated bleaching process [6].

Now, when it comes to bleaching excess right after the treatment, the recorded change in color appearance would be more accurately described as desaturation rather than bleaching. This hypothesis is supported by clinical findings showing that light alone can produce an initial whitening effect, which is, however, not sustained for a long time. This seems to be the most appropriate explanation for faster bleaching after one clinical appointment because no significant benefit of light activation was found between groups after two bleaching sessions. This is consistent with the findings of recent studies reporting that powerful light sources have no effect on the actual speed or extent of bleaching [4].

According to Vildosola, *et al.* the observed immediate tooth lightening that is attributed to tooth dehydration appeared to be more an increase in tooth brightness than a decrease in the level of tooth colorization. For this reason, the color assessments in their study were all performed 1 week following the bleaching treatments for teeth rehydration [7,8].

Color was registered over the middle third of the labial surface as established by the American Dental Association guidelines. Color difference was calculated as the number of shade guide units that the tooth changed into toward the lighter end of the shade guide (Deviations of Shade Guide Units). It is recommended to wait at least 15 minutes for teeth rehydration before color assessment [8].

As we noted, manufacturers incorporate coloring agents or pigments into their products having colors capable of promoting maximum absorption of this light and converting it into heat to increase the interaction of visible light with the bleaching gel. The coloring agents act as selectors or filters, absorbing one or more wavelengths and reflecting others. For this to occur, the pigment or coloring agent must have a specific color, known as the complementary color, which may be observed in the so-called chromatic circle, in which the complementary colors are in a diametrically opposed position. For the gels with red coloring, the complementary color of the light to be used should be green. For the gels with

orange coloring, the complementary color of the light to be used should be blue [9,10].

In the bleaching product we used in the treatment (white smile®), the manufacturer incorporates potassium nitrate, fluoride and Xylitol. It prevents sensitivity and has a very pleasant, fruity taste. The patient ends his tooth bleaching session with a very pleasant feeling - true wellness for the teeth.

Besides, our patient had no intraoperative nor postoperatively sensitivity.

In the study conducted by Calderini A., *et al.* in 2016, in the bleaching gel tested, the manufacturer developed a particular formulation by combining hydrogen peroxide with calcium and strontium ions. This combination resolved the sensitivity problem and the enamel-dentin decalcification by the formation of insoluble salts; in particular, calcium phosphate and oxalate of strontium having affinity with enamel hydroxyapatite and dentinal tubules. This would act against decalcification allowing remineralization of enamel and clogging dentinal tubules.

Despite the advantages offered by bleaching, the effect of the bleaching agents on dental hard tissues is still controversial. A number of studies have evaluated the influence of the bleaching agents on the properties of enamel and dentin. Some chemical products have a lower than ideal pH which can cause changes in the mineral content of the enamel, this in turn promotes or increases enamel erosion or abrasion. However, studies have shown that the addition of fluoride or calcium to the composition of the bleaching agent can minimize mineral loss in hard dental tissues [2].

It is commonly established that combining an ambulatory technique with an immediate one does not only optimize the esthetic result, but also maintains long-term results. That is why such a technique is considered to be the best in lightening therapies. Indeed, in our clinical case, the yellowish background of the fluorosis spots that have persisted following the immediate technique disappeared thanks to Home Bleaching. The result was stable over time. So, the ambulatory technique allowed an homogenization of color; it optimized the esthetic result and maintained it for long-term.

Conclusion

In this case report, the bleaching treatment using a light-irradiating bleaching has shown efficacy and no post-bleaching sensitivity. It demonstrates that light can be a good complement to accelerate the bleaching process [11,12].

More than a week of at home-bleaching using 16% carbamide peroxide is necessary to improve the esthetic result and to sustain the color obtained.

Bibliography

1. Feliz-Matos L, LM Hernandez, N Abreu. Dental Bleaching Techniques; Hydrogen-carbamide Peroxides and Light Sources for Activation, an Update. Mini Review Article. Open Dent J, 2014;8:264-268.
2. Angelo Calderini SS, Chiara Semeria, Giuseppe Pantaleo, Elisabetta Polizzi. Comparative clinical and psychosocial benefits of tooth bleaching: different light activation of a 38% peroxide gel in a preliminary case-control study. Clinical Case Reports. 2016;4(8):728-735.
3. Lima DA, et al. In vitro evaluation of the effectiveness of bleaching agents activated by different light sources. J Prosthodont. 2009;18(3):249-254.
4. Kossatz S, et al. Effect of light activation on tooth sensitivity after in-office bleaching. Oper Dent. 2011;36(3):251-257.
5. Ana Bárbara Araújo Loiola AESG, Renata Siqueira Scatolin, Silmara Aparecida Milori Corona. Impact of hydrogen peroxide activated by lighting-emitting diode/laser system on enamel color and microhardness: An in situ design. Contemporary Clinical Dentistry. 2017;7(3):312-316.
6. Sari T, G Celik, A Usumez. Temperature rise in pulp and gel during laser-activated bleaching: in vitro. Lasers Med Sci. 2015;30(2):577-582.
7. Gurgan S, FY Cakir, E Yazici. Different light-activated in-office bleaching systems: a clinical evaluation. Lasers Med Sci. 2010;25(6):817-822.
8. Vildosola P, et al. Teeth bleaching with low concentrations of hydrogen peroxide (6%) and catalyzed by LED blue (450 +/- 10 nm) and laser infrared (808 +/- 10 nm) light for in-office treatment: Randomized clinical trial 1-year follow-up. J Esthet Restor Dent. 2017;29(5):339-345.
9. Torres CR, et al. Assessment of the effectiveness of light-emitting diode and diode laser hybrid light sources to intensify dental bleaching treatment. Acta Odontol Scand. 2011;69(3):176-181.
10. Carlos Rocha Gomes Torres RMA. Light activation of the bleaching gel tested with the high-intensity LED devices provided more intense bleaching than use of the bleaching gel without light activation. Rev odontol ciênc. 2009;25(2):159-164.

11. Eliseu Aldrighi Münchow TM, Lisia Lorea Valente, Cristina Pereira Isolan and Evandro Piva. In-Office Tooth Bleaching Treatment Using Light-Activated Hydrogen Peroxide Agent: A Case Report. *JSM Dent.* 2013;2(1): 1020.
12. Cunha do Amaral Gonzaga de Almeida R, Lucia Marçal Mazza. Clinical Evaluation of The Effectiveness of Different Bleaching Therapies in Vital Teeth. *Int J Periodontics Restorative Dent.* 2012;32(3):303-309.

Volume 2 Issue 2 February 2019

© All rights are reserved by Ben cheikh Ahmed H., *et al.*