



Case Report: The Clinical Application of Surgical Placement and Restoration with an Irradiated Patient

Aref Almahayni* and Nabeel Rashid

Department of Restorative Dentistry, Edinburgh Dental Institute, Edinburgh, United Kingdom

*Corresponding Author: Aref Almahayni, Department of Restorative Dentistry, Edinburgh Dental Institute, Edinburgh, United Kingdom.

Received: July 04, 2019; Published: July 26, 2019

Abstract

Previous treatment with Radiotherapy has adverse effects on normal host tissue, which in turn limits the availability of restorative options. Risk factors linked to the surgical procedures include Infections (3%), implant loss, poor healing, bleeding and increased bone loss have been reported in most studies on clinical outcomes of dental implants [1]. One of the recognized and severe complications of radiation therapy is Osteoradionecrosis (ORN). Survival of implant supported single crowns in normal healthy patients at 5 years data were 94.5% [2]. While tooth supported fixed-fixed bridge would have had 85% survival at 15 years, it should be noted that increased failure rate when patients have been treated with a high radiotherapy dose (over 60 Gy). The aim of this paper is to show that surgical implants can be placed and restored in irradiated patients when taking into consideration proper planning in low dosage fields.

Keywords: Implants; Radiation; Surgery; Implant Guided; Osteoradionecrosis

Introduction

The patient was keen to improve the aesthetics of his anterior dentition and to replace the lost teeth in the mandibular posterior right side. The challenge presented was the restoration of and missing teeth to allow for acceptable function. The wax up offered a simulation of the procedure the patient was going to have and helped guide the treatment-planning phase. Before going to the mock up stage, the wax up assisted in visualizing shape, size, contour and position of teeth involved in the final rehabilitation treatment. A cone beam CT scan (maxilla/mandible) was also taken in order to assess in the implant and surgical planning. The CBCT showed how much is available in the anterior maxillary region. The scan mapped out important anatomical structures and helped predict implant placement with avoiding any complications. A combination of direct and indirect restorations were considered with the patient to restore anterior aesthetics. A full discussion of conservative and conventional crown and bridge options were discussed including the pros and cons. ideally, a Removable Partial denture option would have replaced the maxillary and mandibular edentulous space with minimal intervention. However, the patient preferred a fixed option. Risk factors linked to the patients local

and systemic factors were discussed along with the mechanical and biological complications.

Case Report

Brief History

Patient had difficulty maintaining his dentition due to cancer treatment for a T4N3 squamous cell carcinoma of lower left mandible. The patient had received a high dosage of radiotherapy and in return lost teeth on the lower and upper left side of the jaw. Patient had recently lost teeth (11 and 46) due to periapical pathology. This had him loose self-confidence and aesthetics was his main concern.

Case treatment

Patient had to be stabilized from a Hygiene point of view, which posed a difficulty due to the severe xerostomia due to the irradiation. After initial hygiene phase therapy was optimal, special investigation including mounted models, radiographs, and a CBCT scan was taken in order to assess implant and surgical planning. A combination of direct and indirect restorations were considered to restore the patient's anterior aesthetics. Surgical dental implant

placement at site 11 was commenced by a prosthetically driven approach. Indirect E-max crowns were placed on teeth 21, 22 with an implant-retained crown placed on implant 11. After completion of treatment, the patient would be reviewed at 6 months.

Discussion

This case was successful in achieving the aims and objectives of restoring a patient that underwent oral cancer treatment to address his aesthetic and functional concerns in a manner that was predictable and holistic. However, many factors needed to be considered in his previous history of Cancer treatment. Even though radiotherapy is related with higher rates of implant failure [3]. The Implant procedure performed had no complications and healing was uneventful after 6 months post-surgery. This in part was due to proper treatment planning and surgical placement of implants in moderate dosage fields (40 GY). Mechanical complications were also discussed such as fracture of the abutment, loosening of the abutment screws, and food impaction. The position of all implants allowed the final restoration to be screw retained and so improved retrievability. The prosthesis were designed to facilitate oral hygiene and ensure the maintenance of implant health. After completion of treatment, the patient would be reviewed at 6 months to assess the following: plaque control; peri-implant probing depth; bone loss; occlusion; presence of soft tissue inflammation. If the patient manages to maintain his low caries rate, then the prognosis of the remaining dentition is good.

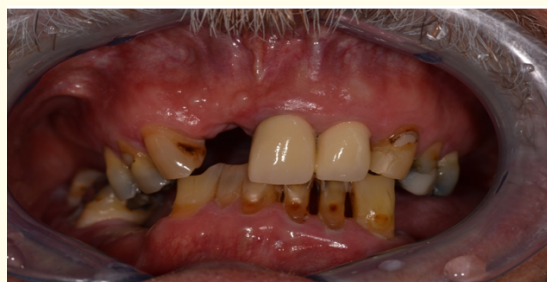

Figure 1: Patient post-surgical treatment of oral cancer.

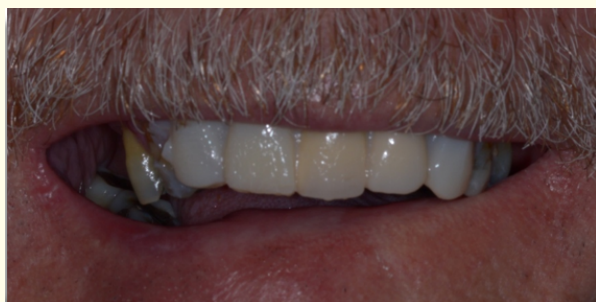

Figure 2: Mock-up with try in.

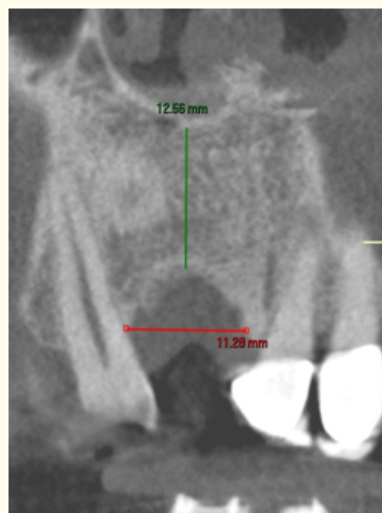


Figure 3: CBCT planning.

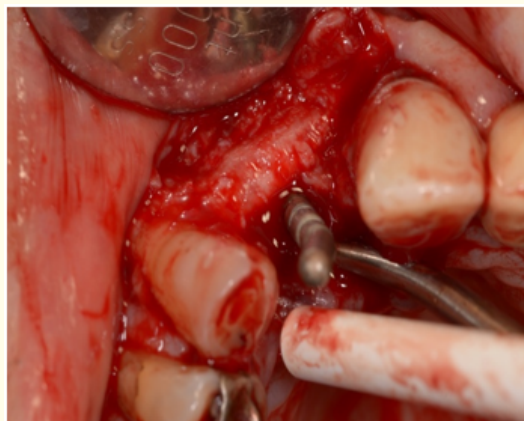

Figure 4: Surgical implant placement (11).

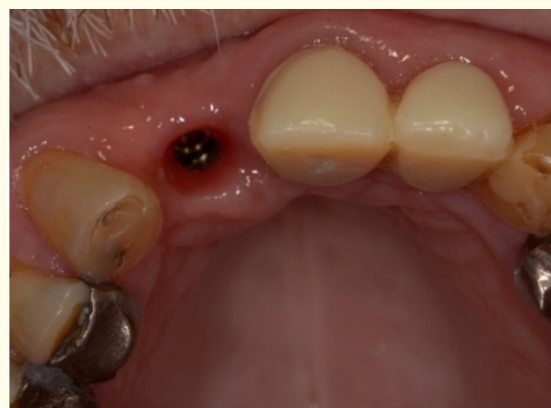


Figure 5: Implant and soft tissue healing.

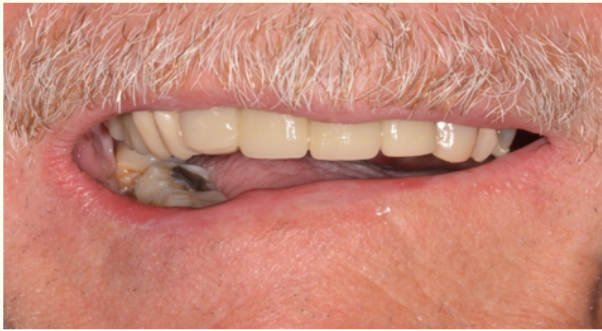

Figure 6: Final restored dentition.

Conclusion

This case was an excellent learning platform for managing the failing dentition in a comprehensive manner and provided experience in both classical and contemporary fixed prosthodontics. The patient was very satisfied with the outcome and now has a maintainable prosthesis that provides reasonable longevity, catering for patients lifestyle, eating pattern, general health and oral hygiene ability and an aesthetic outcome in accordance with patients expectations. Following completion, the key aspects are appropriate recall and maintenance of the newly restored dentition. Even though previous treatment with Radiotherapy has adverse effects in the oral cavity, which in turn limits the availability of restorative options. Implants can be used effectively to help restore function and aesthetics with reasonable outcome if planned and executed in a safely manner.

Bibliography

1. Adell R, Erickson B, Lekholm U, Brånemark PI, Jemt T. A long-term follow-up study of Osseo integrated implants in the treatment of totally edentulous jaws. *Int J Oral Maxillofac Implants.* 1990;5(4):347-359.
2. Maxymiw WG, Wood RE, Liu FF. Post-radiation dental extractions without hyperbaric oxygen. *Oral Surg Oral Med Oral Pathol.* 1991;72(3):270-274.
3. MacInnes A, Lamont T. Radiotherapy associated with higher rates of dental implant loss. *Evid Based Dent.* 2014;15(1):27-28.

Volume 2 Issue 8 August 2019

© All rights are reserved by Aref Almahayni and Nabeel Rashid.