



## Pyogenic Granuloma in Kidney Transplant Patient: Removal by Laser

Irineu Gregnanin Pedron<sup>1\*</sup>, Plínio Jun Iti Yokoyama<sup>2</sup>, Caleb Willy Moreira Shitsuka<sup>3</sup> and Élio Hitoshi Shinohara<sup>4</sup>

<sup>1</sup>Professor of Periodontology, Stomatology, Integrated Clinic and Laser in Dentistry, College of Dentistry, Universidade Brasil, São Paulo, Brazil

<sup>2</sup>Trainee in Oral Surgery and Traumatology, Hospital Regional de Osasco, São Paulo, Brazil

<sup>3</sup>Professor of Pediatric Dentistry, Cariology and Laser in Dentistry, College of Dentistry, Universidade Brasil, São Paulo, Brazil

<sup>4</sup>Professor of Oral Surgery and Traumatology Department, Universidade Ibirapeura and Hospital Regional de Osasco, Brazil

**\*Corresponding Author:** Irineu Gregnanin Pedron, Professor of Periodontology, Stomatology, Integrated Clinic and Laser in Dentistry, College of Dentistry, Universidade Brasil, São Paulo, Brazil, **Email-id:** igpedron@alumni.usp.br.

**Received:** July 15, 2019; **Published:** August 01, 2019

### Abstract

The kidney transplanted patient, who is more susceptible to opportunist infections during immunosuppressive therapy, is considered a patient that requires special dental care. The oral cavity generally presents some stomatologic alterations secondary to the use of cyclosporin A - an immunosuppressive medication normally used, such as drug-induced gingival overgrowth, hairy leukoplakia, neoplasias, periodontal diseases and candidosis. The purpose of this article is to report a case of pyogenic granuloma developed concomitantly with drug-induced gingival overgrowth in a kidney transplanted patient, submitted to surgery with Nd:YAP laser, and followed up for 19 years. The clinical and histopathologic characteristics, incidence and frequency, differential diagnosis, etiopathogenesis and treatment modalities inherent to the lesion were discussed.

**Keywords:** Pyogenic Granuloma; Gingival Overgrowth; Kidney Transplantation; Dentistry; Dental Care

### Introduction

Organ transplants have been performed more frequently, improving the quality and life expectancy, and reducing the morbidity of pre-transplant conditions. Organ rejection is the complication causing most concern after surgery, exposing the patient to its loss. However, the success of transplants is due to immunosuppressive therapy (anti-rejection medication) that is administered throughout life until the patient's death. Among the immunosuppressive agents, cyclosporine A is the one most used. It may be associated with other medications, such as prednisolone and azathioprine [1-5].

Nevertheless, there are some side effects, either systemic or stomatological, that arise from immunosuppressive therapy. They are adverse systemic reactions to Cyclosporin A, such as nephrotoxicity, peptic ulcerations, increased susceptibility to

the opportunist infections and urinary tract infections [6]. With reference to oral alterations, these include hairy leukoplakias, viral (herpes simplex) and fungal (candidosis) infections, increased incidence of malignant neoplasias (lymphoma, epidermoid carcinoma and Kaposi's sarcoma), drug-induced gingival overgrowth and consequently, periodontal diseases and carious lesions [7]. Some of these alterations may develop risks for the transplant patients, since they can be considered susceptible because of the immunosuppressed condition.

However, other alterations may affect transplant patients. Pyogenic granuloma is frequently found in the dental clinic. It is considered a benign, reactional, proliferative process, clinically characterized by exophytic, sessile or pediculated tissue growth, of erythematous to brownish coloring, generally ulcerated and with spontaneous bleeding. There are local irritant trauma or hormonal factors related to the etiopathogenesis. Generally present in the

gingiva of the anterior region of the maxilla, it more frequently affects women, adolescents and young adults. Surgical removal is the treatment method most used [8-12].

### Purpose of the Study

The purpose of the present report was to describe a case of pyogenic granuloma that affected a kidney transplant patient, and was removed by means of Nd:YAP laser.

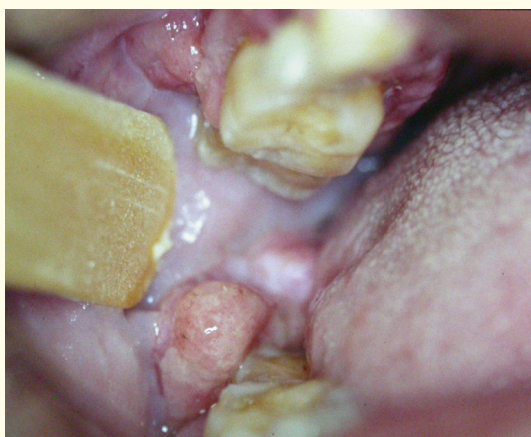
### Case Report

A black male 53-year-old, kidney transplanted 2 years previously, appeared at the private clinic, complaining of a gingival overgrowth. Various medications are administered to the patient daily, among them Cyclosporine A (immunosuppressor), acetyl salicylic acid (platelet anti aggregator), chlortalidone (diuretic), nifedipine and propranolol (anti-hypertensives), prednisolone (corticosteroid) and azathioprine (associated immunosuppressor).

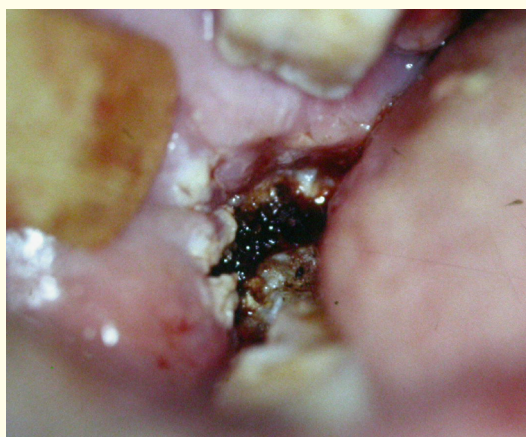
Clinically, the patient presented several tooth losses, precarious oral hygiene, accumulation of dental biofilm and calculus, and keratinized gingival tissue growths, characteristic of drug-induced gingival overgrowth level 3 [3], resulting from the administration of cyclosporine A, which developed after 6 months from the beginning of immunosuppressor treatment. Exophytic and pediculated tumoral masses were observed, located in the fornices and vestibular mucosa in the lower molar region and retromolar trigone, which caused the patient discomfort with mastication and phonation (Figure 1). The teeth presented mobility. Radiographically, horizontal and angular alveolar bone losses were found.

The patient was submitted to basic periodontal therapy and surgery (gingivectomy, used for removal of the drug-induced gingival overgrowth), under prophylactic antibiotic (cephalexin), using 3% mepivacaine chloride without vasoconstrictor as local anesthetic. The nephrologist contraindicated the diclofenac group of analgesics and anti-inflammatory medications. The patient was warned of possible recurrence of the gingival overgrowth because of the medication.

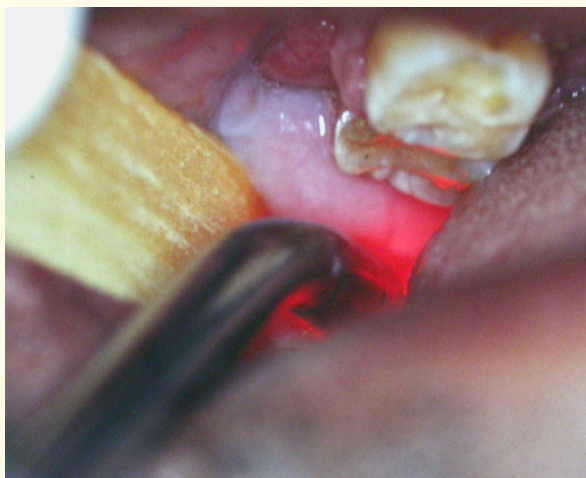
With normalization of the periodontium, surgical removal of the lesions existent in the fornice and vestibular mucosa region was indicated. Because of the difficult access to the lesions, removal by laser was opted for, with due care to send the tissues for histopathologic exam. Under local anesthesia, removal was performed, using laser Nd:YAP (Lokki Dt Laser™, France) [13]. Power of 250 mJ and 30 Hz frequency were used to incise the lesions at the pedicle and to promote immediate hemostasis (Figure 2). After surgery, low level laser therapy (Dentoflex™, São Paulo, Brazil) - 4 J/cm<sup>2</sup> - was applied, in punctiform applications covering the entire area of surgery, with the purpose of promoting faster cicatrizing repair without discomfort to the patient, thus reducing the post-operative symptoms, inflammation and edema (Figure 3). The fragments of the lesions removed were fixed in 10% formol and sent to the Surgery Pathology Laboratory (Department of Stomatology, School of Dentistry, University of São Paulo). Histopathologic exam revealed a fragment of mucosa covered by stratified squamous epithelium, presenting highly vascularized granulation tissue; presence of fibrinous exudate, inflammatory infiltrate cells and characteristic fibroblasts (Figure 4). The final diagnosis was pyogenic granuloma.



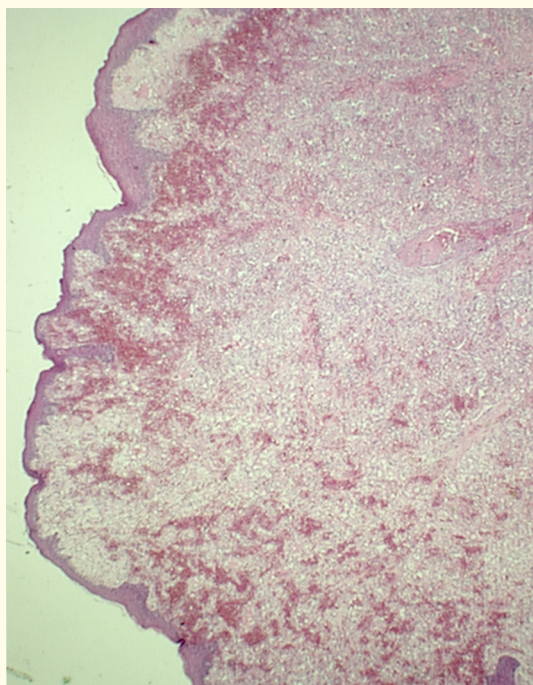
**Figure 1:** Pyogenic granuloma in the retro-molar trigone area on the right side.



**Figure 2:** Immediate post-surgery period with the use of Nd:YAP laser.



**Figure 3:** Application of the low level laser therapy immediately after pyogenic granuloma removal by Nd:YAP laser.



**Figure 4:** Histopathology of pyogenic granuloma (Original coloring: HE; smaller magnification).

At present, the patient has been followed up for 19 years (annual clinical evaluations), support periodontal therapy is being carried out, and there are no signs of recurrence of the lesions.

## Discussion

The pyogenic granuloma presents ample synonymy, receiving the following denominations: vascular epulides, benign vascular tumor, Crocker and Hartzells disease and hemangiomas granuloma [9]. However, the term pyogenic is inadequate, because there is no pus formation in the lesion [10]. During gestation, it is commonly called gravidarum or gravidic granuloma, epulide or gestational tumor [8,9,11,12,14,15].

Pyogenic granuloma is clinically characterized by a tumoral mass or a exophytic soft tissue nodule; sessile or pediculate base; well circumscribed; of erythematous or brownish coloring, depending on the lesion maturity; with a hemorrhagic appearance and tendency to bleeding; smooth or lobulated surface, usually ulcerated by necrosis and covered by a membrane of purulent collection, originating the name of the lesion; soft and resilient consistency when it is young and more fibrous when it is mature, caused by obliteration of the capillaries; with rapid growth, and able to cause bone resorption. It generally affects the gingiva, although it may occur on lips, tongue, oral mucosa, palate and edentulous areas. It ranges from a few millimeters to several centimeters, and when it attains large dimensions, it may interfere in the physiologic activities of the oral cavity [8-12,14-17]. In children, the pyogenic granuloma may be more aggressive, fast growing, and cause bone reabsorption, interfere in tooth eruption and cause dento-alveolar alterations [10,12].

It is more frequent in the gingiva in the anterior region of the maxilla. It affects adolescents and young adults, with 60% incidence in the age range from 11 to 40 years [11]; without predilection for race; women were twice more affected than men [9-12,14-17]. Around 50% of pregnant women presented gingival alterations, but only 0.2 to 5% developed localized tumors [14, 15,17]. Atypical situations may be observed, as present simultaneously with the drug-induced gingival overgrowth, in a kidney transplanted patient under Cyclosporine A therapy (similar to the present report) [11]; or the pyogenic granuloma affecting the tongue of a patient with neurofibromatosis (Von Recklinghausen's disease) [16].

Considered a reactionary inflammatory process with exuberant fibrovascular proliferation of connective tissue, the histopathologic pattern is composed of an ulcerated stratified squamous epithelium; granulation tissue with numerous capillaries, lined by endotheliocytes; presence of fibrinous exudates; inflammatory

infiltrate cells (lymphocytes, plasmocytes, histiocytes and neutrophils) and fibroblasts were characteristic [8-12,14,15,17], as may be observed in figure 4. The possibility of invasion by non-specific microorganisms was suggested [9]. There is no histopathologic distinction between the pyogenic and the gravidic granuloma, and they vary only under the conditions inherent to the etiopathogenesis [15,17].

With reference to etiopathogenesis, the reactional proliferative process results from trauma; local irritation, such as poor oral hygiene, dental biofilm and calculus accumulation, gingival inflammation, periodontal diseases and outstanding restoration margins; and hormonal alterations, such as in pregnancy [8-12,14-17] and in the menarche [12]. In pregnancy, it normally originates in the 2<sup>nd</sup> or 3<sup>rd</sup> trimesters, and tends to develop afterwards [8,11,17]. The use of oral contraceptives that increase the hormone levels and create a state of "pseudo-pregnancy" also was cited [17]. The increase in progesterone and estrogen levels produces dilation and proliferation of the gingival microvasculature and the destruction of mastocytes, resulting in an increased release of vaso-active substances in the adjacent tissue, thus inducing the formation of the granuloma [14,15]. Reduced keratinization of the epithelium of inserted gingiva was also reported, leaving it more vulnerable to trauma, causing a tendency to the growth of vascular tumor of the gingiva and alveolar mucosa [15]. Five polypeptides (Tie-2, angiopoietin-1, angiopoietin-2, ephrin-B2, ephrin-B4) played an important role in the inflammatory neo-vascularization process [11].

Among the lesions that compose the differential clinical diagnosis, there is inflammatory gingival hyperplasia, giant cell peripheral granuloma, peripheral ossifying fibroma, hemangioma, lymphoma, nevus flammeus, Kaposi's sarcoma, metastatic tumor, parulide, hemangioendothelioma, hemangiopericytoma, leiomyoma, infection by cytomegalovirus, gingival lesions by bacillus, periodontal abscess and fistula [11,12,14,17]. Two cases of pyogenic granulomas associated with encephalo-trigeminal angiomas (Sturge-Weber's Syndrome), which could make it difficult to elucidate the diagnosis, if histopathology were not performed [14]. However, pyogenic granuloma is considered the commonest proliferative process of tissue growths [11]. Because of the amplitude of differential diagnosis, the need for histopathologic exam to verify and elucidate the diagnosis was suggested [9] and this is also recognized by the authors of this study.

Surgical removal was the most used treatment modality [8-12,14-17], generally associated with removal of the local irritant factors, such as basic periodontal therapy. The authors suggest that periodontal treatment be carried out before surgery is performed, because of minimizing the inflammatory process, making the surgical procedure easier, reducing abundant bleeding, in addition to reducing the possibility of lesion recurrence [8,11,14,15,17]. Gingivectomy was recommended in conjunction [8,11]. The use of laser (CO<sub>2</sub> and Nd:YAG) was also mentioned, heightening the advantages of the latter in comparison with the conventional surgical technique, such as the reduced risk of post-operative bleeding, pain, discomfort and edema [15,16,18]. In the present report, Nd:YAP laser was used, whose wavelength of 1.340 nm, presents a proposal of multiple uses for general dental clinic, enables its use in various areas: Endodontics, Dentistry, Periodontics, and Oral Surgery, among other specialties. The Nd:YAP laser is transmitted by silica fiber optic; because of its wavelength, it is well absorbed by the tissues, enabling instantaneous volatilization of the surface tissue with minimum carbonization. The absence or minimal occurrence of post-operative edema and pain; promotion of hemostasis, sterilization and exact incision without bleeding, were undoubtedly advantages of this advanced therapeutic resource [13]. The need for a free gingival graft for root covering and loss of keratinized gingiva resulting from surgical removal of the pyogenic granuloma was reported [17] and must be individualized, case by case. The use of chlorhexidine mouth washes improves the post-operative period, by avoiding possible post-surgery infection and inflammation [12,15]. Removal of the lesion base with the purpose of preventing recurrence, and vigorous curettage of the granulation tissue after extractions were recommended [9,11]. There may be regression of the lesion after the birth of the child, in cases of gestational granuloma [14]. Clinical follow up and oral hygiene supervision during the pregnant period have been recommended, if the lesion is small, asymptomatic and without bleeding [15,17].

Follow up of 18 to 24 months, without recurrence, has been mentioned [9,15,17]. Recurrence was related to non-removal of the local irritant factors and the partial removal of the lesion [10,11,15] and was calculated to be around 14 to 16% [9]. In the present report, the patient's gingival overgrowth could be classified as grade 3 which, requires surgical intervention to improve the gingival outline and reduce the accumulation of dental biofilm and calculus [3]. Periodontal control and maintenance can prevent inflammation and recurrence of gingival overgrowth [1,2,4], as has been done in the present case for the past 19 years (annual clinical evaluations).

## Conclusions

Based on the clinical evidence, it may be concluded that:

1. Pyogenic granuloma normally presents clinical and histopathologic characteristics, typical incidence and frequency, although this report has shown an atypical presentation.
2. Pyogenic granuloma is not only a lesion that affects pregnant women or patients with local trauma, and demonstrates that not every gingival overgrowth in transplanted patients undergoing immunosuppressive therapy (Cyclosporine A) is drug-induced gingival overgrowth.
3. The ample clinic differential diagnosis institutes the need for performing the histopathologic exam and this is usually elucidative.
4. Surgical removal is the technique most used, although laser surgery is promising. In the present report, because of the patient's immunosuppressed condition, laser surgery was elected as the first choice, both due to difficult access to the lesion and the added benefits, such as hemostasis, reduced post-operative discomfort, edema and pain, as well as the application of low level laser therapy, because of the analgesic and anti-inflammatory effects.

## Bibliography

1. Pernu HE, Hannele Pernu LM, Knuutila LE. Effect of periodontal treatment on gingival overgrowth among cyclosporine A-treated renal transplant recipients. *J Periodontol.* 1993;64(11):1098-1100.
2. Ilgenli T, Atilla G, Baylas H. Effectiveness of periodontal therapy in patients with drug-induced gingival overgrowth. Long-term results. *J Periodontol.* 1999;70(9):967-972.
3. Inglés E, Rossmann JA, Cafesse RG. New clinical index for drug-induced gingival overgrowth. *Quintessence Int.* 1999;30(7):467-473.
4. Hernández G, Arriba L, Lucas M, De Andrés A. Reduction of severe gingival overgrowth in a kidney transplant patient by replacing cyclosporin A with tacrolimus. *J Periodontol.* 2000;71(10):1630-1636.
5. James JA, Boomer S, Maxwell AP, Hull PS, Short CD, Campbell BA, Johnson RWG, Irwin CR, Marley JJ, Spratt H, Linden GJ. Reduction in gingival overgrowth associated with conversion from cyclosporin A to tacrolimus. *J Clin Periodontol.* 2000;27(2):144-148.
6. Seymour RA, Thomason JM, Ellis JS. Oral and dental problems in the organ transplant patient. *Dent Update.* 1994;21(5):209-212.
7. Seymour RA, Thomason JM, Nolan A. Oral lesions in organ transplant patients. *J Oral Pathol Med.* 1997;26(7):297-304.
8. Falabella MEV, Falabella JM. Granuloma gravídico-caso clínico. *Rev Periodontia.* 1994;3(2):167-170.
9. Graham RM. Pyogenic granuloma: an unusual presentation. *Dent Update.* 1996;23(6):240-241.
10. Rivero ELC, Araújo LMA. Granuloma piogênico: uma análise clínico-histopatológica de 147 casos bucais. *RFO UPF.* 1998;3(2):55-61.
11. Al-Zayer M, Fonseca M, Ship JA. Pyogenic granuloma in a renal transplant patient: case report. *Spec Care Dent.* 2001;21(5):187-190.
12. Ramirez K, Bruce G, Carpenter W. Pyogenic granuloma: case report in a 9-year-old girl. *Gen Dent.* 2002;50(3):280-281.
13. Lokki DT Laser. *Laser para Clínica Geral em Odontologia. Manual do proprietário.* 1996.
14. Ilgenli T, Canda T, Canda S, Unal T, Baylas H. Oral giant pyogenic granulomas associated with facial skin hemangiomas (Sturge-Weber Syndrome). *Periodontal Clin Investig.* 1999;21(2):28-32.
15. Silva-Sousa YTC, Coelho CMP, Brentegani LG, Vieira MLSO, Oliveira ML. Clinical and histological evaluation of granuloma gravidarum: case report. *Braz Dent J.* 2000;11(2):135-139.
16. Modica LA. Pyogenic granuloma of the tongue treated by carbon dioxide laser. *J Am Geriatr Soc.* 1988;36(11):1036-1038.

17. Silverstein LH, Burton CH, Garnick JI, Singh BB. The late development of oral pyogenic granuloma as a complication of pregnancy: a case report. *Compend Contin Educ Dent.* 1996;17(2):192-198.
18. Pinheiro ALB, Frame JW. Tratamento cirúrgico de patologias moles do complexo maxilo facial. In: Brugnera Jr A, Pinheiro ALB. *Lasers na Odontologia Moderna.* São Paulo: Pancast Editora, 1998:177-192.

**Volume 2 Issue 9 September 2019**

**© All rights are reserved by Irineu Gregnanin Pedron, et al.**