

Frequency of Haller's Cells and Relationship with Non-Odontogenic Maxillary Sinusitis Using Cone Beam CT

Fateme Azimi*

Oral and Maxillofacial Radiologist, Arak, Iran

***Corresponding Author:** Fateme Azimi, Oral and Maxillofacial Radiologist, Arak, Iran.

Received: December 05, 2019; **Published:** December 23, 2019

Abstract

Awareness of frequency of Haller's cells is important for ostiomeatal unit and endoscopic surgeons because these cells can eliminate access in Functional Endoscopic Sinus Surgery (FESS) and may cause operation complications. In this study Investigation among existing CBCT images has the advantage of precise detection of haller's cells and radiographic signs of maxillary sinusitis avoiding superimpositions and possible technical errors occur in panoramic radiography.

This study included existing CBCT data of 200 outpatients (100 men and 100 women) of an oral and maxillofacial radiology center between 2018 to 2019.

Among 6 patients with unilaterally right sinusitis, 2 patients showed left haller's cells and 2 patients showed bilateral haller's cells.

Of 52 patients with bilateral sinusitis, 2 patients demonstrated left haller's cells, 4 showed right haller's cells and 2 showed bilateral haller's cells.

This study found 19% frequency of haller's cells. In this study association between existence of haller's cells and non-odontogenic maxillary sinusitis is not statistically significant. Predisposing factors for narrowing of infundibulum should be evaluated individually.

Keywords: Haller's Cells; Sinusitis; CBCT

Introduction

Infraorbital ethmoid cells also known as orbitomaxillary cells or haller's cells are pneumatized ethmoid air cells that project along the medial roof of the maxillary sinus and the most inferior portion of the lamina papyracea, below the ethmoid bulla and lateral to the uncinate process. These cells were first identified by Haller in 1765.

Although haller's cells defined as anatomical variations, many authors believe these cells as a factor in recurrent maxillary sinusitis because they contribute to the narrowing of the infundibulum and may also compromise the adjacent ostium of the maxillary sinuses. However, some researchers found no statistical difference between the frequency of haller's cells in patients presenting with recurrent maxillary sinusitis and asymptomatic patients.

Awareness of frequency of Haller's cells is important for ostiomeatal unit and endoscopic surgeons because these cells can eliminate access in Functional Endoscopic Sinus Surgery (FESS) and may cause operation complications [1,2].

Some studies investigated frequency of haller's cells by panoramic views [1,3-5].

This study has used cone-beam computed tomography as a low dose, accurate and inexpensive modality to investigate frequency of haller's cells and to describe relationship between existences of these cells and maxillary sinusitis. In this study Investigation among existing CBCT images has the advantage of precise detection of haller's cells and radiographic signs of maxillary sinusitis avoiding superimpositions and possible technical errors occur in panoramic radiography.

Materials and Methods

This study included existing CBCT data of 200 outpatients (100 men and 100 women) of an oral and maxillofacial radiology center between 2018 to 2019. Since the maxillary sinuses enlarge during childhood and achieving mature size by the age of 15 to 18 years, patients with age under 18 were excluded and age range of samples was between 18 and 88.

The patients underwent CBCT examination for dental implant treatment using NewTom VGi (Quantitative Radiology, Verona, Italy), FOV 8*12 cm and voxel size of 0.25 mm. Patients with a history of trauma and/or surgery involving the maxillofacial region, systemic diseases affecting growth and development, or clinical and/or radiographic evidence of developmental anomalies/pathologies affecting the maxillofacial region were excluded from the study.

Reconstructed coronal CBCT images with thickness of 0.5 mm were evaluated for the presence of haller's cells that defined as pneumatized ethmoid air cells project along the medial roof of the maxillary sinus and the most inferior portion of the lamina papyracea, below the ethmoid bulla and lateral to the uncinate process (Figure 1).

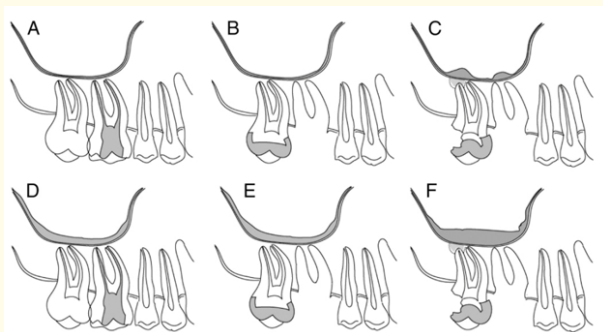


Figure 1: (A and B) Normal sinus mucosal thickening of less than 2 mm. Adjacent teeth may be healthy, carious, pulp exposed, restored, extracted, and with or without radiographically evident periapical lesion. (C) Sinusitis of an odontogenic origin. Mucosal thickening limited to carious tooth, tooth with defective restoration with or without radiographically evident periapical lesion, or extraction site. (D and E) Sinusitis of a nonodontogenic origin. Mucosal thickening is not limited to any tooth, periapical lesions, or extraction socket. (F) Sinusitis of an undetermined origin. A possible odontogenic source is present, but mucosal thickening is not limited to any carious tooth, tooth with defective restoration, a periapical lesion, or a disrupted socket [6].

Non-odontogenic maxillary sinusitis is radiographically diagnosed according to Michelle Mailet., *et al* [6]. A soft-tissue density mass within the sinuses is considered as non-odontogenic sinusitis when fulfills the following criteria: Teeth are non-carious, have coronal and/or endodontic restorations of good quality without radiographic evident of periapical lesion or if extracted, intact or healing socket and mucosal thickening are not limited to any tooth [6] (Figure 2).

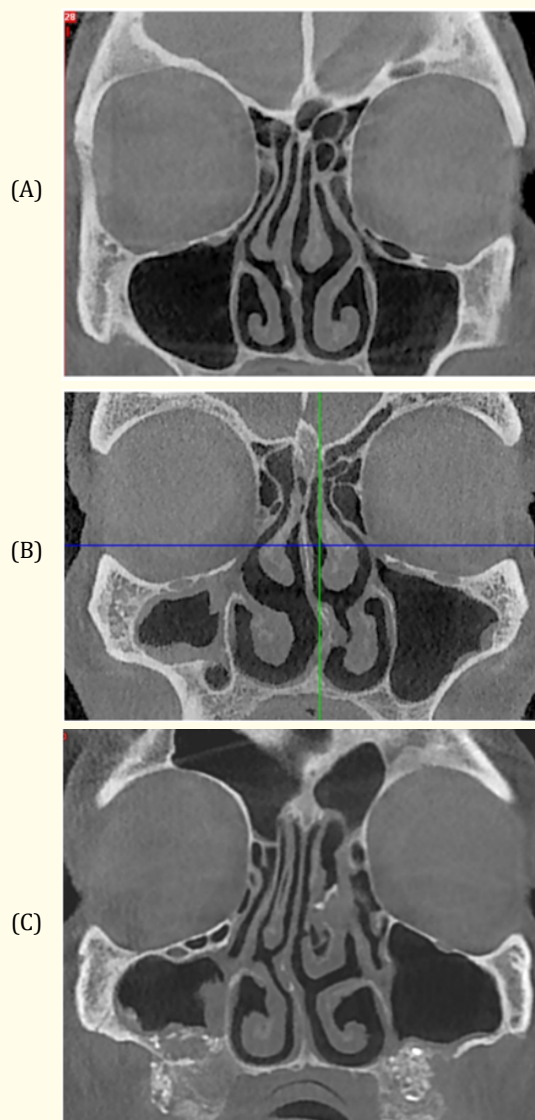


Figure 2: Coronal Sections of CBCT Images, Showing A) Left Haller's Cell and no Maxillary Sinusitis. B) Right Maxillary Sinusitis and No Haller's Cell. C) Right Haller's Cell and Right Maxillary Sinusitis.

Statistical analysis

Chi-square test was used to find out the association between the presence of the Haller cells and non-odontogenic maxillary sinusitis. P value of < 0.05 was considered to be statistically significant.

Results

Of the 200 patients (100 women and 100 men), 38 (19%) patients with haller's cells were found.

Of 38 patients with haller's cells, 28 (14%) patients showed these cells unilaterally and 10 (5%) bilaterally.

In cases with unilateral haller's cells, these cells occurred on the right side in 12 patients (43%) and on the left side in 16 (57%) patients.

Mean age of studied patients and mean age of patients with haller's cells were 48.8 ± 17.6 and 44 ± 16.7 , respectively.

The frequency of haller's cells was not different regarding gender and age.

Among 200 studied patients, 58 (29%) patients were found with non-odontogenic maxillary sinusitis detected on CBCT images. 6 (3%) patients showed this finding unilaterally in right maxillary sinus. No non-odontogenic maxillary sinusitis was found unilaterally in left maxillary sinus. 52 (26%) patients involved bilaterally.

Among 6 patients with unilaterally right sinusitis, 2 patients showed left haller's cells and 2 patients showed bilateral haller's cells.

Of 52 patients with bilateral sinusitis, 2 patients demonstrated left haller's cells, 4 showed right haller's cells and 2 showed bilateral haller's cells.

No patient was found with maxillary sinusitis only on the left side.

Discussion

This study found 19% frequency of haller's cells by evaluating CBCT images of 200 patients that is almost half of frequency recorded by Valizadeh basis on panoramic radiographs [3]. Some other studies Ahmad., *et al.* [4] and Khayam., *et al.* [5] showed 38.2% and 32.5% frequency of haller's cells on panoramic ra-

diographs, respectively. It is not unlikely that technical errors and overlapping of structures may affect the author's judgment in mentioned studies. The limitations of panoramic radiographs analysis are well known and include magnification, geometric distortion, superimposition of structures, projective displacements (which may elongate or foreshorten an object's perceived dimensions), rotational errors and linear projective transformation [7].

Many researchers have evaluated haller's cells using CT and CBCT modalities and have been reported a wide range of frequency (4.7% to 45.1%) in CT [8] to 60% (CBCT, Mathew) [9]. This may be explained by Variation in study populations, different subjective judgments and various sample sizes.

Using CT images, Kumar [8], Earnwaker [10] and Ghaffari R [11] reported frequency of these cells, 22.8%, 20% and 11.6%, respectively. These different results could be explained variation of samples and different CT Techniques.

Nowadays, comparatively low dosing requirements and high-quality bony definition by CBCT scanners have made them attractive for scanning of the paranasal sinuses. Some studies have investigated frequency of haller's cells on CBCT images. Mathew *et al.* and Reinhard E Friedrich [12] Found 60% and 23.62% frequency of haller's cells, respectively.

The most recent study using CBCT for detecting haller cells and its association with maxillary sinus pathologies, reported 49% of haller's cells frequency and concluded the presence of these cells are related to maxillary sinus pathologies like sinusitis [13].

Authors of current study think it is very important to discriminate types of sinusitis based on causes. Odontogenic sinusitis occurs related to inflamed maxillary teeth and doesn't have association with infundibulum narrowing by haller's cells. Furthermore present study excluded all kinds of odontogenic sinusitis according to Michelle Mailet., *et al.* (Figure 1) [6].

This study found the frequency of haller's cells was not significantly different regarding gender. This finding is compatible with Raina., *et al.* [1], Ghaffari., *et al.* [11] and Khayyam., *et al.* [5] and is Inconsistent with Valizadeh [3] study on panoramic radiography.

Some authors considered haller's cells as a factor in recurrent maxillary sinusitis by narrowing of the infundibulum and compromising the adjacent ostium of the maxillary sinuses [13]. Ghaffari R [11] however some other studies reported there is no relationship between these cells and sinus diseases [10,14,15].

Results of current study demonstrated the relationship between maxillary sinusitis and haller's cells is not statistically significant (p value = 0.005) that is in line with Mathew, *et al*, Arslan, *et al*, Bolger, *et al*. and Earnwaker [9,10,14,15].

Some researchers expressed the clinical significance of haller's cells although often considered as a possible predisposing factor in chronic sinusitis and pressure headache because of osteomeatal narrowing, has not been fully determined.

The role of haller's cells in disease should be examined on an individual basis, depending on the size, placement, and evidence of inflammation in the cell [16].

Mathew expressed no association of haller's cells between presence, size and maxillary sinusitis could indicate that maxillary sinusitis is primary condition than resulting from narrowing of maxillary sinus ostia and there is no statistically significant association between the existence of Haller's cells and maxillary sinusitis. They believed explanation of maxillary sinusitis on the basis of mechanical obstruction is unlikely [9].

Conclusion

This study found 19% frequency of haller's cells. In this study association between existence of haller's cells and non-odontogenic maxillary sinusitis is not statistically significant. Predisposing factors for narrowing of infundibulum should be evaluated individually.

Bibliography

1. Raina A, MV Guledgud, K Patil. Infraorbital ethmoid (Haller's) cells: a panoramic radiographic study. *Dentomaxillofac Radiol.* 2012;41(4):305-308.
2. Stammberger HR, DW Kennedy. Paranasal sinuses: anatomic terminology and nomenclature. *Ann Otol Rhinol Laryngol Suppl.* 1995;167:7-16.
3. Valizadeh S, Maryam Mostafavi, Sara Ehsani, Sepideh Goorang. Visibility of infraorbital ethmoid air cell on panoramic radiographs. *J Dent Sch.* 2010;28:7-11.
4. Ahmad M, Khurana N, Jaber J, Sampair C, Kuba RK. Prevalence of infraorbital ethmoid (Haller's) cells on panoramic radiographs. *Oral Surg Oral Med Oral Pathol Oral Radiol Endod.* 2006;101(5):658-661.
5. Ehsan Khayam, Amir Mohamad Mahabadi, Fatemeh Ezoddini, Mohamad Ali Golestani, Zeinab Hamzeheil, Malihe Moeini, Seyed Hossein Razavi. The prevalence of ethmoidal infraorbital cells in panoramic radiography. *AJRC.* 2013;1(2):109-118.
6. Maillet M, Bowles WR, McClanahan SL, John MT, Ahmad M. Cone-beam computed tomography evaluation of maxillary sinusitis. *J Endod.* 2011;37(6):753-757.
7. Laine FJ, WR Smoker. The ostiomeatal unit and endoscopic surgery: anatomy, variations, and imaging findings in inflammatory diseases. *AJR Am J Roentgenol.* 1992;159(4):849-857.
8. Prem Kumar KS, R Sudarshan, G Sree Vijayabala, Samuel Raj Srinivasan, Prajna V Kini. A Study on the Assessment of Haller Cells in Panoramic Radiograph. *Niger Med J.* 2018;59(3):25-27.
9. Mathew R, Omami G, Hand A, Fellows D, Lurie A. Cone beam CT analysis of Haller cells: prevalence and clinical significance. *Dentomaxillofac Radiol.* 2013;42(9):20130055.
10. Earwaker J. Anatomic variants in sino nasal CT. *Radiographics.* 1993;13(2):381-415.
11. Ghaffari R, SHEikhi M, Zarrabi H, Safi H. Prevalence of Infraorbital Ethmoid (Haller's) Air Cell on CT Image in Patients over 6 years of age. *J Res Dent Sci.* 2010;7 (2):14-19.
12. Friedrich RE, M Fraederich, G Schoen. Frequency and volumetry of infraorbital ethmoid cells (Haller cells) on cone-beam computed tomograms (CBCT) of the mid-face. *GMS Interdiscip Plast Reconstr Surg DGPW.* 2017;6:Doc07.
13. Pallavi Kamdi, Vijayalakshmi Nimma, Amit Ramchandani, Easwaran Ramaswami, Ajas Gogri, Hemant Umarji. Evaluation of haller cell on CBCT and its association with maxillary sinus pathologies. *JIAOMR.* 2018;30(1):41-45.
14. Bolger WE, CA Butzin, DS Parsons. Paranasal sinus bony anatomic variations and mucosal abnormalities: CT analysis for endoscopic sinus surgery. *Laryngoscope.* 1991;101(1 Pt 1):56-64.
15. Arslan H, Aydinlioğlu A, Bozkurt M, Egeli E. Anatomic variations of the paranasal sinuses: CT examination for endoscopic sinus surgery. *Auris Nasus Larynx.* 1999;26(1):39-48.
16. Wanamaker HH. Role of Haller's cell in headache and sinus disease: a case report. *Otolaryngol Head Neck Surg.* 1996;114(2):324-327.

Volume 3 Issue 1 January 2020

© All rights are reserved by Fateme Azimi.