



Diode Laser Lingual Frenectomy in Pediatric Dentistry: Case Report

Sophia Rana de Souza Medeiros Lima¹, Alessandra Baptista², Hatsuo Kubo³, Caleb Shitsuka⁴ and Irineu Gregnanin Pedron^{5*}

¹Undergraduate Student, Universidade Brasil, São Paulo, Brazil

²Professor, Post-graduation in Bioengineering, Universidade Brasil, São Paulo, Brazil

³Professor and Head, School of Dentistry, Universidade Brasil, São Paulo, Brazil

⁴Professor, Department of Pediatric Dentistry and Cariology, Universidade Brasil and Faculdades Metropolitanas Unidas, São Paulo, Brazil

⁵Professor, Department of Periodontology, Implantology, Stomatology, Laser and Therapeutics, School of Dentistry, Universidade Brasil, São Paulo, Brazil

***Corresponding Author:** Irineu Gregnanin Pedron, Professor, Department of Periodontology, Implantology, Stomatology, Laser and Therapeutics, Universidade Brasil, São Paulo, Brazil. **E-mail:** igpedron@alumni.usp.br

Received: September 23, 2020; **Published:** October 14, 2020

Abstract

Frenectomy, treatment performed in the indication of the excision of the labial or lingual frenum, presents several trans and postoperative complications, when the conventional surgical methods are used. The high power laser has been increasingly used in several dental specialties. The purpose of this article was to present a clinical case of lingual frenectomy using the diode laser (=980 nm) for the surgical procedure associated with photobiomodulation in a 7 years-old female patient in order to promote better trans and post-surgical conditions, illustrating particularly these benefits to children patients.

Keywords: Labial Frenum; Lingual Frenum; Lasers; Laser Biostimulation; Laser Coagulation

Introduction

The lip frenum, in many cases is related to the presence of diastemas and can also make it difficult to perform oral hygiene by promoting accumulation of biofilm that induces gingivitis and subsequently periodontitis, in addition to reducing the amount of keratinized gingiva. The lingual frenum in turn can cause ankyloglossia that provokes a series of functional and social disorders [1,2].

Frenectomy is a surgical procedure that aims to remove the frenum allowing both orthodontic movement to close diastemas, as well as adequate movement of the tongue necessary for functional activities. The removal of the lingual frenum is frequently requested by speech therapist [1]. It should be performed early, as soon as the diagnosis is obtained, preventing or minimizing the implications related to poor dental positioning and muscle development,

which may be impaired. Besides surgical treatment, complementation through orthodontic and speech therapy is often necessary to restore normal physiology (occlusion, chewing, swallowing and phonation) of the stomatognathic complex. It should be noted that if not performed early, it can compromise the psychosocial well-being [1].

For dental care, especially in pediatric dentistry, the use of simpler, faster, more precise and less invasive techniques to the patient is always the best option. The frenectomy performed with the high power laser is undoubtedly a procedure that fills these requirements due to the great advantages inherent to its use, from the need for less anesthetic, such as the absence of bleeding, greater ease of viewing the surgical site and decontamination of the surgical wound [1-5].

The use of laser is comprehensive and its use is increasing every day in dentistry and other medical sciences [1]. The approval of the use of laser in dental surgeries in soft tissues in 1990 by the FDA (Food and Drug Administration), is an example of the recognition of the benefits of this technology [1].

Several types of lasers are used in dentistry. Each type of laser has different physical characteristics that influence the interaction of light with the target tissues producing specific effects [1]. The erbium, argon, carbon dioxide (CO₂), diode and neodymium lasers have optical affinity mainly with water and hemoglobin. Therefore, they are considered excellent "cutters". They are indicated in surgical procedures such as frenectomy, gingivoplasty, gingivectomy, clinical crown augmentation, ulectomy and because they are high power lasers, through the thermal effect, they are able to promote the decontamination of the treated region [7,8]. They can be used in focused or unfocused mode, depending on the clinical indication. In focus mode, the light interacts in greater depth and smaller action diameter, promoting a more precise cutting function. In the unfocused mode, the light interacts mainly in the superficial layers of the tissues, which provides interaction with a larger surface area promoting the ablation or vaporization of tissues, much used for the removal of white lesions such as leukoplakia, hyperkeratosis or in the removal of carious tissue [8].

The use of diode semiconductor lasers (gallium arsenide - GaAs; gallium-aluminium arsenide - GaAlAs) in soft tissue surgeries has gained popularity in recent years. They are compact, portable surgical units with efficient and reliable benefits. They also have reduced costs, in comparison with the other types of lasers, which allowed a greater diffusion of this technique in dental offices. The photons are produced by electric current with wavelengths that vary between 810, 940 and 980 nm [1]. These wavelengths are highly absorbed by hemoglobin and melanin and have little absorption in hard tissues, which provides selective action of light allowing precise cuts, coagulation and vaporization of areas around dental structures and better postoperative healing [1,3]. Moreover, the application of diode lasers reduces the need for anesthesia, controls significantly bleeding and does not require sutures [3]. The delivery of light is done through a flexible optical fiber that varies from 200 to 600 µm in diameter, facilitating the ergonomics and precision of the procedures.

The purpose of this article is to present a case of lingual frenectomy using a diode laser (=980 nm) in a 7-year-old female patient.

Case Report

A 7-year-old female Caucasian patient attended at the dental clinic of Universidade Brasil, accompanied by her mother, with an indication for lingual frenectomy, at the request of the orthodontist.

Clinically, the patient presented persistent lingual frenum with insertion in the lingual mucosa in the region of the mandibular symphysis (Figure 1). Periodontal health adjacent to the surgical site was observed and no systemic changes were reported.

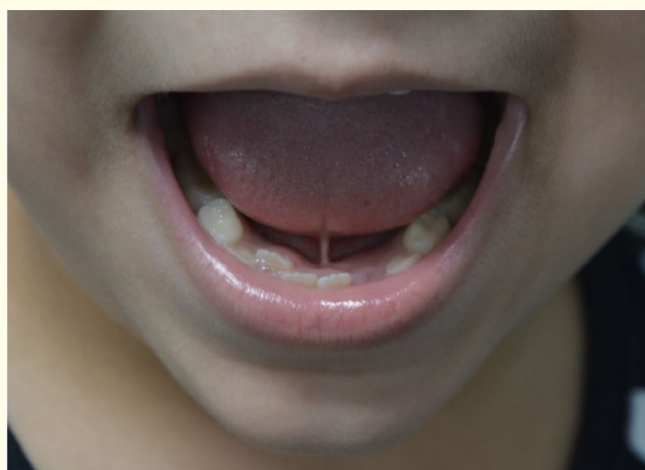

Figure 1: Lingual frenum: upper view.

The proposal to use the laser to perform the frenectomy occurred mainly because she was a pediatric patient and because of the various benefits provided by the use of the technique. After the application of topical anesthetic, infiltrative anesthesia was performed in the region of the insertion of the mandibular symphysis and complemented on the sides of the lingual frenum. The device used was a diode semiconductor laser (Thera Lase Surgery®, DMC, São Carlos, Brazil, P = 1.2 W) (Figure 2). This protocol met the technical specifications recommended by the owner's manual, as well as the care and precepts inherent to biosafety and safety procedures for the use of the laser (Figure 3).

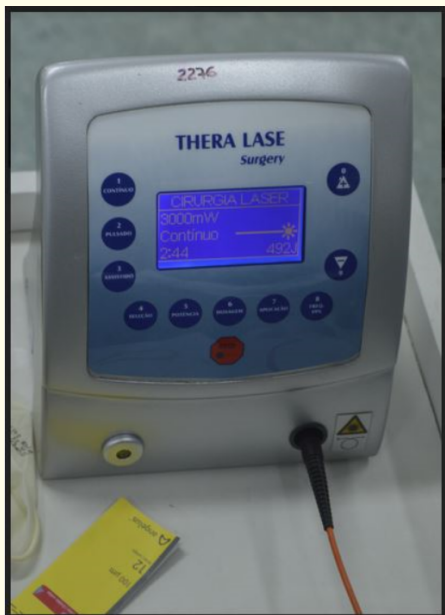

Figure 2: Diode laser.

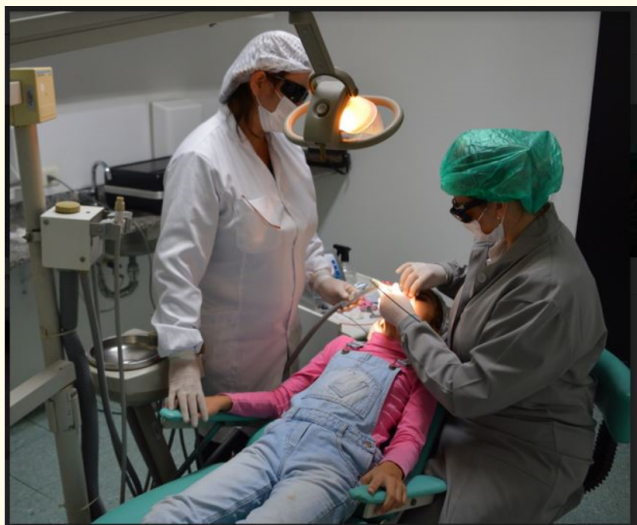

Figure 3: Biosafety practices inherent to the use of laser in dentistry.

The area of the lingual frenum was gently removed with controlled lateral movements (Figure 4) and the carbonized tissue was carefully removed with wet gauze (Figure 5). Tissue removal was evaluated according to the lingual movement, by laterality, elevation and extrusion (Figure 6). Immediately after the total removal of the fibrous tissue, the fiber of the equipment was changed and the area was irradiated in a punctual way with the low power laser (P = 100 mW), in order to cover the whole extension of the surgical site (3 J per point). The post-surgical laser therapy was performed with the purpose of promoting the photobiomodulation, which provides the acceleration of the healing process and the reduction of inflammatory symptoms.

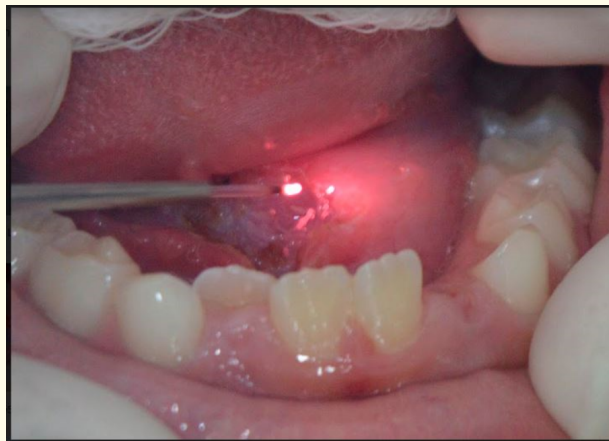


Figure 4: Removal of fibrous tissue from the lingual frenum.

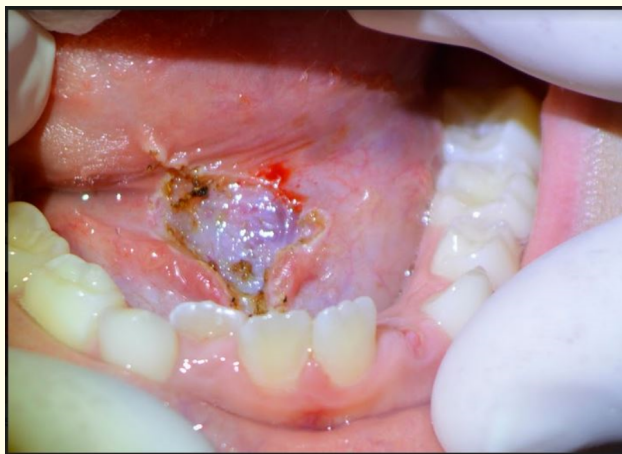

Figure 5: Carbonized tissue was carefully removed with wet gauze.

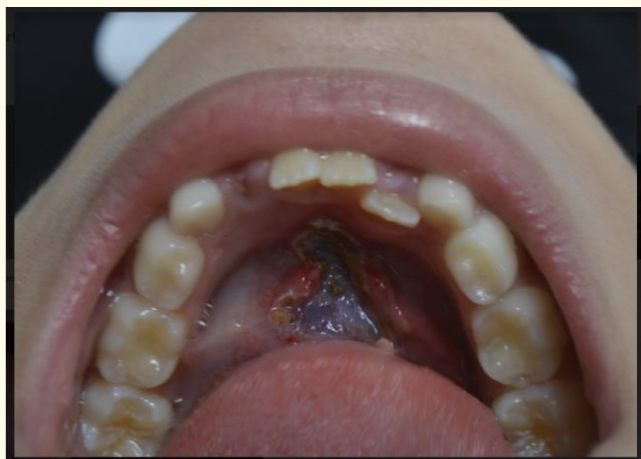

Figure 6: Immediate post-surgical: evaluation of the lingual movements.

After 30 days post-surgery, tissue repair of the site was observed and no complaints or discomfort were reported by the patient in the immediate postoperative period.

Discussion

Besides frenectomy, the high power diode laser can be used in several soft tissue interventions such as: gingivectomy; gingivoplasty; ulotomy; ulectomy; clinical crown augmentation; reopening and access to the implant; incision for drainage of oral abscesses; biopsy; hemangioma and other vascular, necrotic and pigmented lesions; eruption cysts; and in decontamination of the periodontal pocket [3,6,9,11]. The low power laser has been used in dentistry in treatments with analgesic, anti-inflammatory and repairing purposes such as aphthous ulcer, traumatic injury, herpetic lesion, mucositis, temporomandibular dysfunction, post-surgical, paresthesia, facial palsy, among other indications [8-10].

The use of the high power laser for surgeries presents several benefits in relation to conventional surgical techniques, since it cuts, vaporizes, coagulates and sterilizes the surgical site. The ease of its use and the reduction of the surgical time reduce the local trauma during the intervention. It promotes hemostasis by blocking and coagulating small vessels in the incision line and reduces the post-surgical symptomatology and is of great acceptance by

the patients, because it reduces their apprehension in the face of a surgery without scalpel. It promotes the decontamination of the site through the thermal effect and eliminates the need for sutures avoiding trans and post-surgical infections. It reduces the amount of anesthesia and in some cases, the procedures can be performed using only topical anesthetic [5]. Studies have shown that there was a reduction in the need for anesthesia in approximately 55% of the procedures in soft tissue surgeries performed with high power laser [11].

In the case of pediatric dental surgery, the use of high power laser has reported benefits in relation to conventional techniques such as fast and effective treatment, which reduce stress and trauma to the child patient [2,9,10].

Frenectomy with high power laser has been widely studied by several authors, regardless of the type of surgical laser used [2,9,10]. In a study performed in 150 patients, in which frenectomies were performed, the qualitative and quantitative postoperative symptomatology was evaluated. Sixty-eight percent of the patients reported no symptoms, while 32% of the patients reported some symptoms and among these, 83% used analgesic (oral) for up to 48 hours [12]. Another study performed with 20 pediatric patients, between 8 and 10 years-old, submitted to frenectomy with high power laser showed that all patients reported no post-surgical pain or minimal discomfort and no post-surgical bleeding. Also, 100% of the patients reported that the procedure was well tolerated and "acceptable", with no recurrence after 4 years of evaluation [9].

During the surgical procedure with high power laser, small blood and lymphatic vessels are sealed due to the thermal effect, reducing or eliminating bleeding and edema. Histologically, the removal and displacement of epithelial tissue, the presence of coagulated and necrotic epithelial remains, occluded vessels and edematous endotheliocytes may be observed in the area of coagulated tissue adjacent or surrounding the surgical area. The repair process is initially determined by the formation of a sero-fibrinous clot, rich in fibronectin and without red blood cells filling the site [11]. This "clot" serves to protect the wound from bacterial or frictional action. Clinically, during 48-72 hours after surgery, this layer

is hydrated by saliva and disintegrates revealing the formation of a new epithelialized tissue [11].

The use of laser therapy after the surgical procedure induces local photobiomodulation and can be a satisfactory alternative to stimulate the process of tissue repair [9].

Conclusion

We can conclude that the use of high-power diode laser associated with photobiomodulation can be a satisfactory alternative to conventional surgical techniques for lingual frenectomy procedures in pediatric patients, providing better trans and post-surgical conditions.

Bibliography

1. Edwards JG. The diastema, the frenum, the frenectomy: a clinical study. *Am J Orthod.* 1977;71(5):489-508.
2. Pedron IG, Guerreiro RB, Antunes AS, Baptista A. Frenectomia labial com laser de diodo em Odontopediatria: relato de caso. *Rev Maxillaris Portugal.* 2019;14(96):46-53.
3. Derikvand N, Chinipardaz Z, Ghasemi S, Chiniforush N. The Versatility of 980 nm diode laser in Dentistry: A case series. *J Lasers Med Sci.* 2016;7(3):205-208.
4. Komori S, Matsumoto K, Matsuo K, Suzuki H, Komori T. Clinical study of laser treatment for frenectomy of pediatric patients. *Int J Clin Pediatr Dent.* 2017;10(3): 272-277.
5. Kafas P, Stavrianos C, Jerjes W, Upile T, Vourvachis M, Theodoridis M, Stavrianou I. Upper-lip laser frenectomy without infiltrated anaesthesia in a paediatric patient: a case report. *Cases J.* 2009;2:7138.
6. Park S. Lasers and soft tissue: 'fixed' soft tissue surgery. *Br Dent J.* 2007;202:247-253.
7. Garcez AS, Ribeiro MS, Núñez SC. Laser de Baixa Potência - Princípios básicos e aplicações clínicas na Odontologia. Rio de Janeiro: Elsevier. 2012:259.
8. Martens LC. Laser physics and a review of laser applications in dentistry for children. *Eur J Paediatr Dent.* 2011;12(2):61-67.
9. Genovese WJ, Moreira LA, Bordini PJ, Zampieri MJP, Ardohain RS, Fernandes DR. Estudo comparativo clínico entre os lasers cirúrgicos Neodímio-YAP e CO₂ na remoção de hemangioma e hiperplasia fibrosa inflamatória. *Rev Assoc Paul Cir Dent.* 2002;56:27.
10. Garg N, Verma S, Chadha M, Rastogi P. Use of carbon dioxide laser in oral soft tissue procedures. *Natl J Maxillofac Surg.* 2015;6(1):84-88.
11. Pirnat S. Versatility of an 810 nm diode laser in Dentistry: An overview. *J Laser Health Acad.* 2007:4.
12. Ortega-Concepción D, Cano-Durán JA, Peña-Cardelles JF, Paredes-Rodríguez VM, González-Serrano J, López-Quiles J. The application of diode laser in the treatment of oral soft tissues lesions. A literature review. *J Clin Exp Dent.* 2017;9(7):e925-e928.

Volume 4 Issue 1 January 2021

© All rights are reserved by Irineu Gregnanin Pedron, et al.